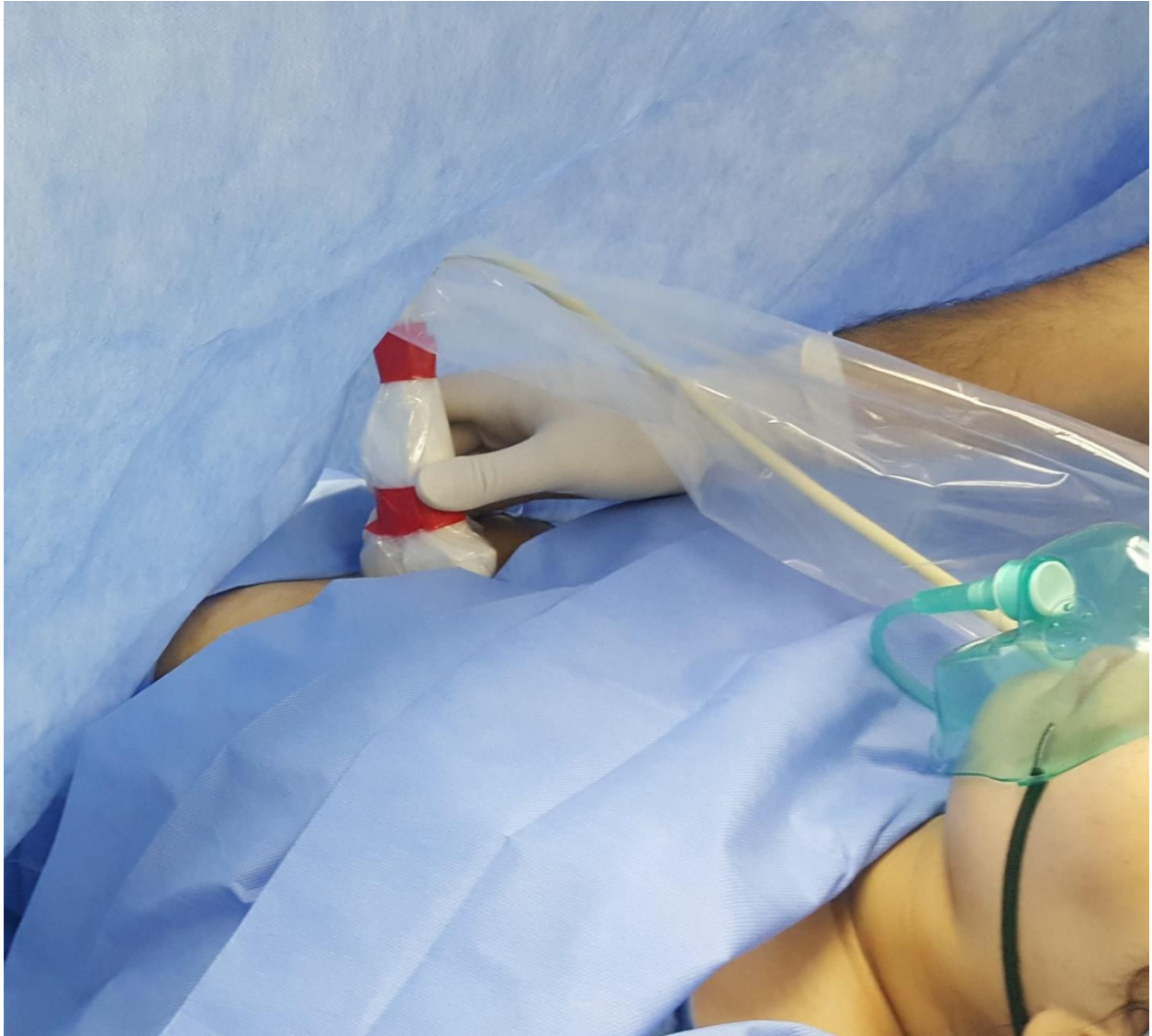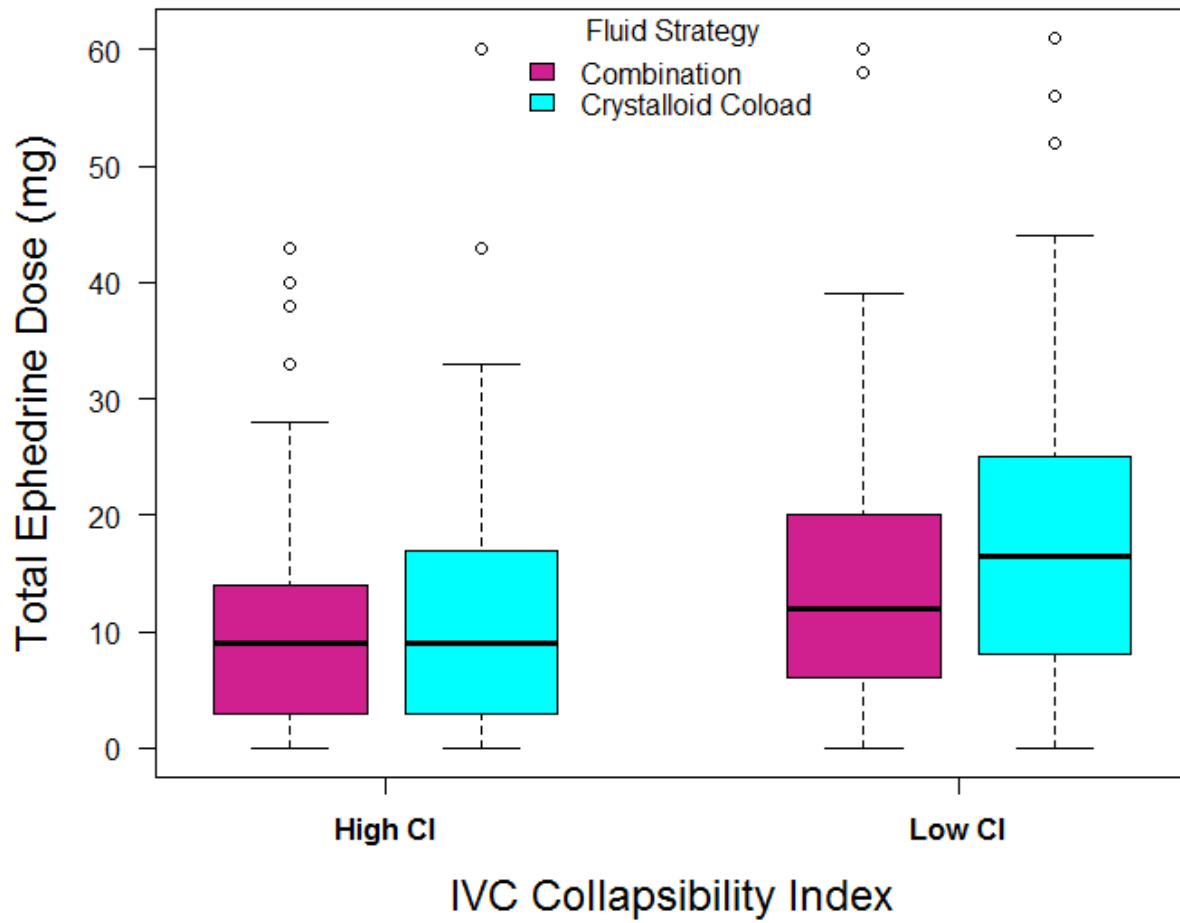


Supplemental Figure 1.

A photograph demonstrating ultrasound scanning of the inferior vena cava intraoperatively.



Supplemental Figure 2.

Box plots of subjects with a high and low inferior vena cava (IVC) collapsibility index (CI) subdivided according to the strategy of fluid administration. No significant differences were found between subjects receiving different fluid strategies in either CI group.