

Supplemental Digital Appendix 1

Short-Answer Physical Exam Worksheet for Students in Medical Gross Anatomy at Virginia Commonwealth University School of Medicine

Physical Exam of Your Cadaver

Task: Fill in the blanks based on information you obtain from examining your cadaver.

Identification:

In the autopsy room, the decedent would be identified by a hospital toe tag/and wrist band. In the dissection lab, provide the Dissection Table # _____ and Cadaver tag # _____ (usually a square, brass tag with a number embossed on it).

Provide an estimate of: Weight ____ lbs?, Height ____ inches?
Age at death _____ (will be provided by Anatomy staff)

****Begin a detailed survey of your cadaver with it in supine (face-up) position, then turn it over to prone (face-down) position.****

General

Provide a general assessment of nourishment:

Obese _____; Normal _____; or Under-nourished _____?

Skin

Describe (and sketch onto Body Diagram) the location, size, and contour of scars, ulcers, contusions/ecchymoses, birthmarks, indwelling implants and tattoos (increased risk of Hepatitis B/C).

Head

What is the color of the hair _____? Distribution of the hair (e.g., bald/normal) _____.

Open the eyelids. Are the eyes intact (they may have been harvested for donation) _____?

Are the nares of the nose clear (or occluded with blood/mucus) _____?

Open the mouth and examine the teeth. Are most of the teeth present _____? Is the cadaver edentulous (lacks all teeth) _____? Are there full/partial dentures present (remove if present) _____?

Neck

In the anterior midline of the neck, palpate the laryngeal prominence (voice box) and then examine the area immediately below (inferior) to it for the thyroid gland. Is the thyroid gland enlarged (could be indicative of Grave's disease/hyperthyroidism) _____? Inferior to that, is there a surgical opening to the trachea present (tracheostomy, tracheotomy) _____? More laterally at the root of the neck, are there indwelling Intrajugular catheters present _____?

NOTE: At the root of the neck, usually on the right side, there is a post-mortem cut-down made by the embalmer to administer embalming fluids.

Thorax

Examine the chest for the presence of a Chest tube _____? a Subclavian catheter _____? or a bulge of subcutaneously implanted Pacemaker _____? Look for the presence of a mid-sternal scar (indicative of heart surgery) _____? Palpate the right and left clavicles to where they nearly meet in the midline, at the sternal notch. Continue palpating in an inferior direction from the sternal notch across the sternum. Notice that the sternum exhibits a slight angle, termed the sternal angle. At the sternal angle is located the articulation with the 2nd ribs (right and left). Using that as a landmark, palpate and count the ribs (hard to the touch) and intercostal spaces (soft-feeling spaces between ribs) until you reach the costal margin (border between thorax and abdomen). Using palpation, how many ribs can you count on one side between the sternal angle and the costal margin _____? Knowledge of this coordinate system (ribs and spaces) is important for placement of EKG leads.

If your cadaver is female, examine the breasts for possible palpable masses _____? Note if one or both breasts are present _____?

Abdomen

The anterior abdomen may contain a large amount of fat in some cadavers and will be difficult to examine further. Are there surgical scars in the right upper quadrant of the abdomen (indicative of gall bladder surgery) _____? right lower quadrant (indicative of appendix surgery) _____? horizontal just above the pubis (indicative of C-section delivery or hysterectomy) _____? Try to determine if there are any regional asymmetries near the lower border, or inguinal region, which may represent an inguinal hernia _____? Or near the umbilicus, which may represent an umbilical hernia _____.

Upper Limb:

Examine the arm, forearm and hand for deformities _____? Are the knuckles (Metacarpophalangeal joints) swollen (indicative of arthritis) _____? Look for subcutaneous bruising on the dorsum of the hand _____, the anterior wrist/forearm _____, or cubital fossa (at elbow) as indicators of IV catheters? Are there signs of clubbing of the fingers _____? or staining of the fingernails (due to heavy tobacco smoking) _____?

Lower Limb:

Examine the thigh, knee, leg and foot for deformities _____? Surgical scars across the hip can be indicative of hip replacement surgery _____? Surgical scars at the knee are indicative of a variety of knee surgery or replacement. Look at the medial (inner) surface of the leg/calf for a long, curving scar which could indicate that the saphenous vein had been harvested for various forms of arterial bypass surgery (usually for coronary bypass) _____? Are all the toes present (toe amputation can be the result of advanced diabetes) _____?

Male Genitalia:

Penis: un/circumcised _____?

Scrotum: Testes present and bilaterally descended _____? Symmetrically/asymmetrically distended or swollen (may represent hydrocele) _____?

Female Genitalia:

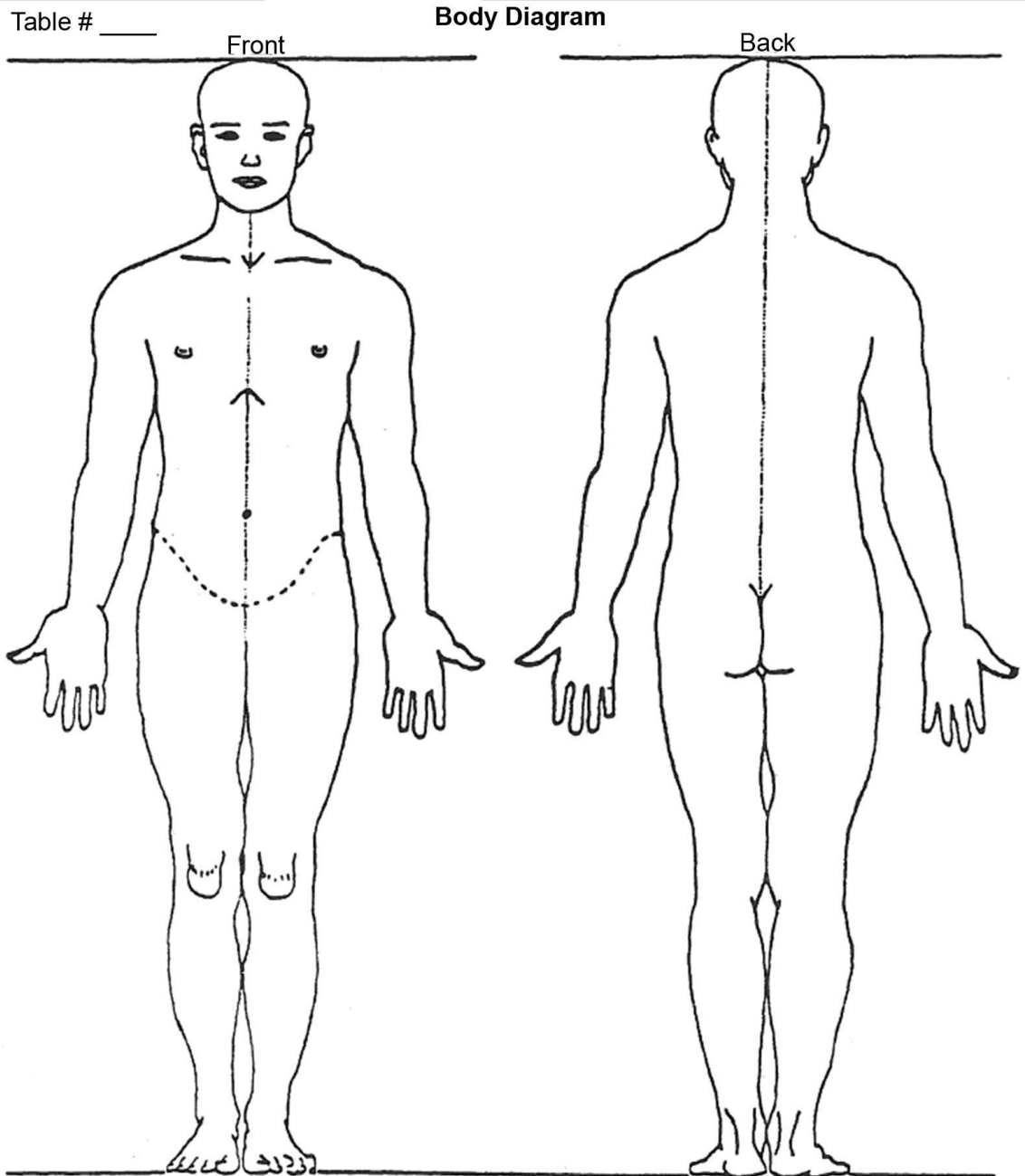
Vulva and vagina, usually symmetrical with smooth mucosa _____?

****Turn the cadaver to face-down (prone) position to examine the back.*

*Leave cadaver in this prone position to be ready for the first dissection exercise. ****

Back:

Examine the midline of the back for straightness and symmetry (deviations can represent scoliosis, which is a deformation of alignment of the vertebral column) _____? At points where the bones in this region are only minimally padded by skin/muscle (posterior shoulder; lower back/sacrum), look for ulcers in the skin that can be produced by prolonged bed-rest (decubitous ulcers, a.k.a. bed sores) _____?



Indicate location of scars, wounds, implants, amputations, etc.

Supplemental Digital Appendix 2

Scoring Rubric for Clinical Faculty Who Serve as Evaluators of Student Cadaver Rounds Presentations at Virginia Commonwealth University School of Medicine

Scoring Rubric for Cadaver Rounds Final Presentation

Points Value	3	2	1	0	Points Score
Major clinical finding(s) Presented	Clinical finding(s) clear, well-identified and significant	Multiple clinical findings identified but none receive focused attention	Clinical finding unclear; or insignificant	Interpretation of clinical finding incorrect.	
Organization and Clarity	Points clearly related to and support main thesis; points/ideas emerge through logic; transitions are direct and appropriate	Points relate well to thesis; emerge fairly logically; most transitions are effective and direct. No rambling.	Points/ideas only tangentially applicable; logical progression vague; rambles somewhat	No main points are identifiable; lacks logical progress; no transitions; Rambles.	
Accuracy	Excellent knowledge base; uses relevant literature/theory to support thesis	Good knowledge base; often uses relevant literature to support thesis	Acceptable understanding of literature/theory; may effectively relate some areas of thesis	Little to no understanding of literature/theory; inadequate or inaccurate use of literature to support thesis	
Multiple resources	Cites >6 texts, photos, graphs, radiographs/refs; from different disciplines	Cites 4-6 references; from >1 discipline	Cites 4-6 references; mostly from single discipline	Cites few references; mostly from single discipline	
Verbal Communication	Language/syntax always correct, applicable, error free and direct.	Language/syntax consistently correct, applicable and mostly error free and direct	Language/syntax sometimes correct; many errors of usage	Language/syntax inappropriate or incorrect; indirect	
Visual Communication	Visual aids are appropriate, referred to consistently, of High visual quality	Visual aids are appropriate, occasionally referenced or of average quality	Visual aids are appropriate but few referenced or of low visual quality	Visual aids are irrelevant, reference rarely made to them, low visual quality	
Responses to Questions	Response prompt, thorough, respectful and clear.	Response adequate, but could be enhanced with further elaboration	Response expresses unease or impatience; imprecise or inadequate answer	Response unclear, unable to correctly answer, misconstrued the questions	
Overall Presentation	CREATIVE; presenters enthusiastic and professional; no one reads from slides; does not exceed time limit	Acceptable in all categories; no one reads from slides; presentation does not exceed time limit	All team members present; some read from slides or presentation exceeds time limit	Some team members missing, or uninvolved; presentation exceeds time limit	Sum Total <input type="text"/>