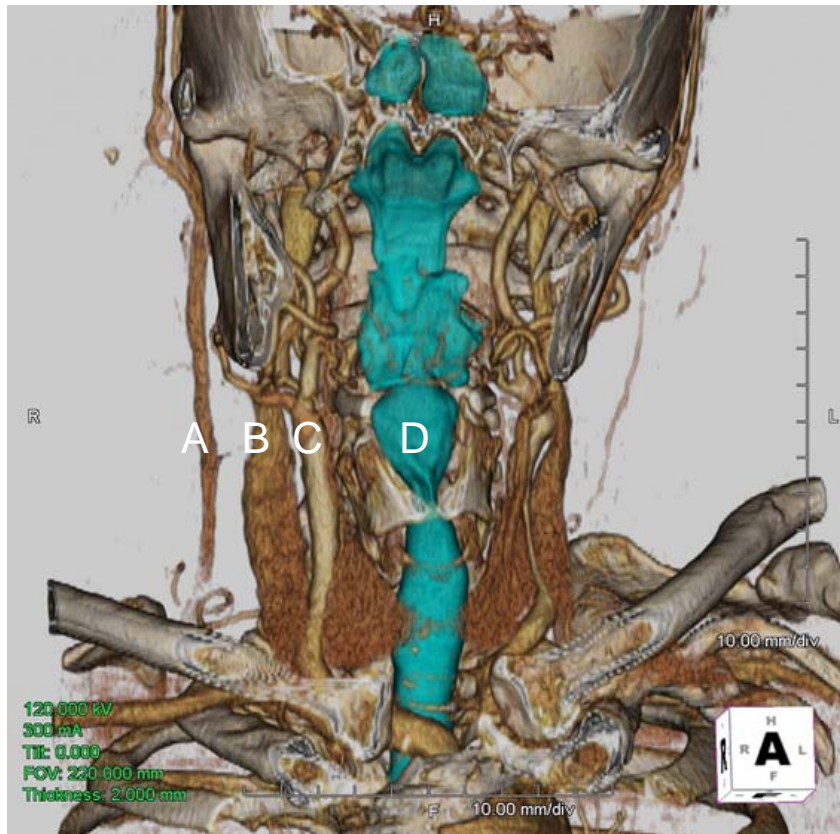


Supplemental Digital Content 1. Three-dimensional CT image of the human neck.



Common carotid arteries are about 1 cm lateral from the pharynx and upper esophagus. A: external jugular vein, B: internal jugular vein, C: common carotid artery, D: pharynx