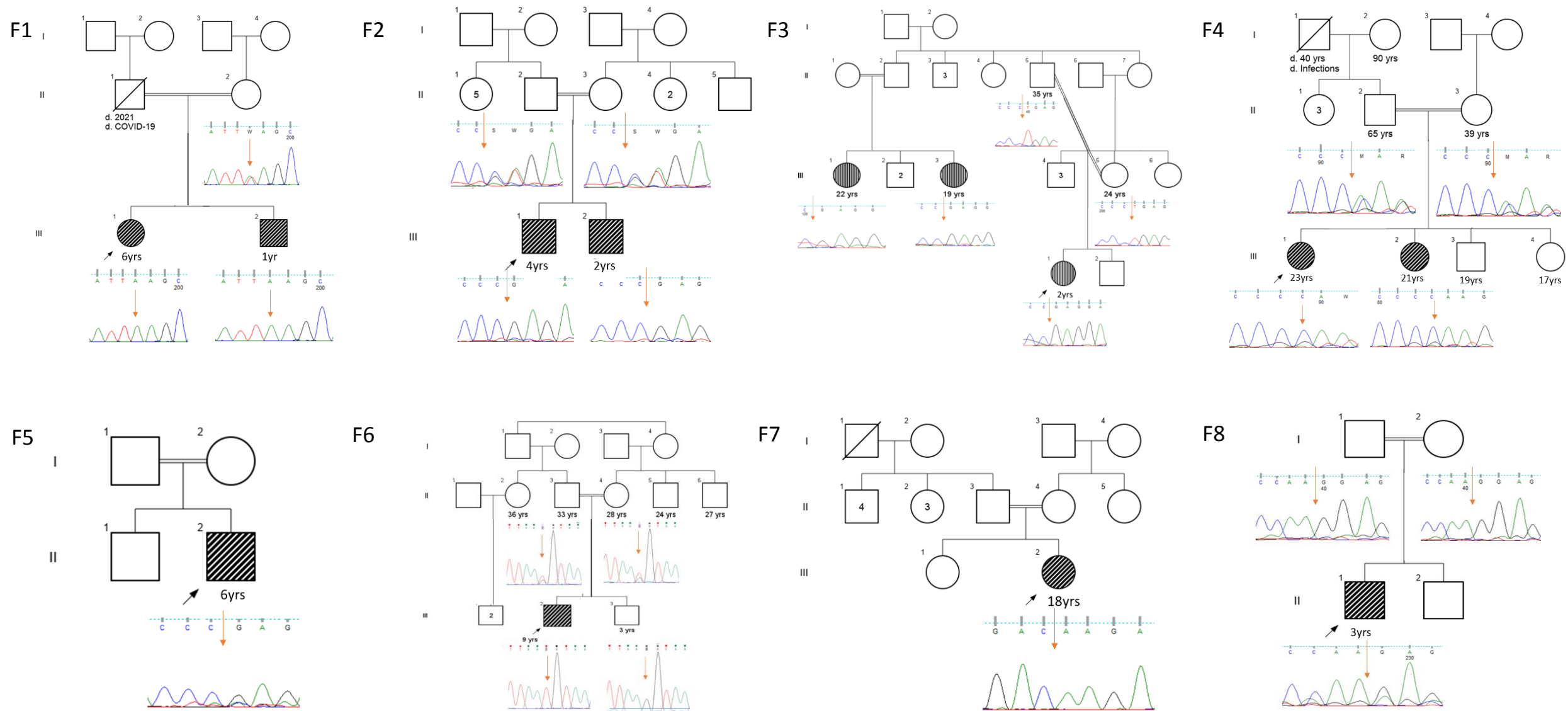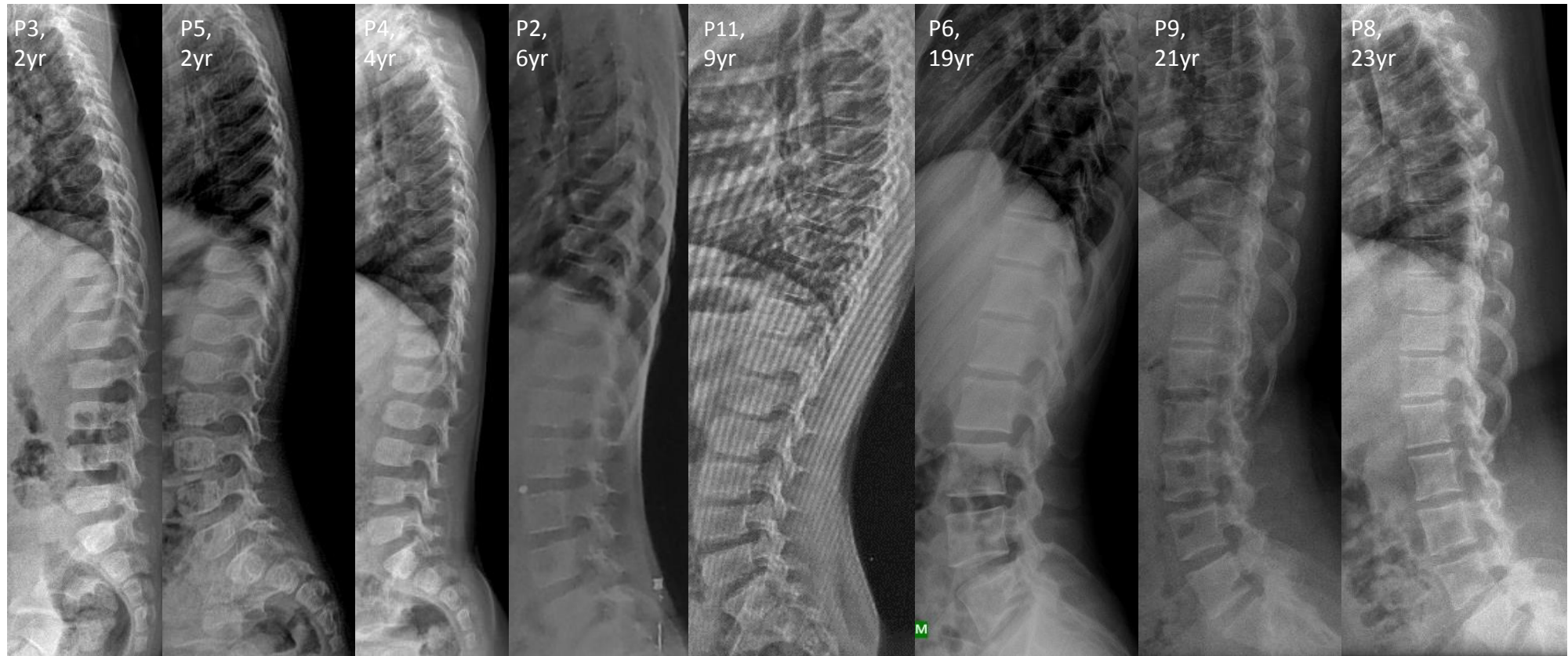


Supplementary figure 1: Pedigrees of 8 families and Sanger sequencing chromatograms showing segregation pattern of disease causing variants in respective pedigrees.



Supplementary figure 2: Spine radiographs are mostly unremarkable. Lumbar lordosis is more pronounced in P11.