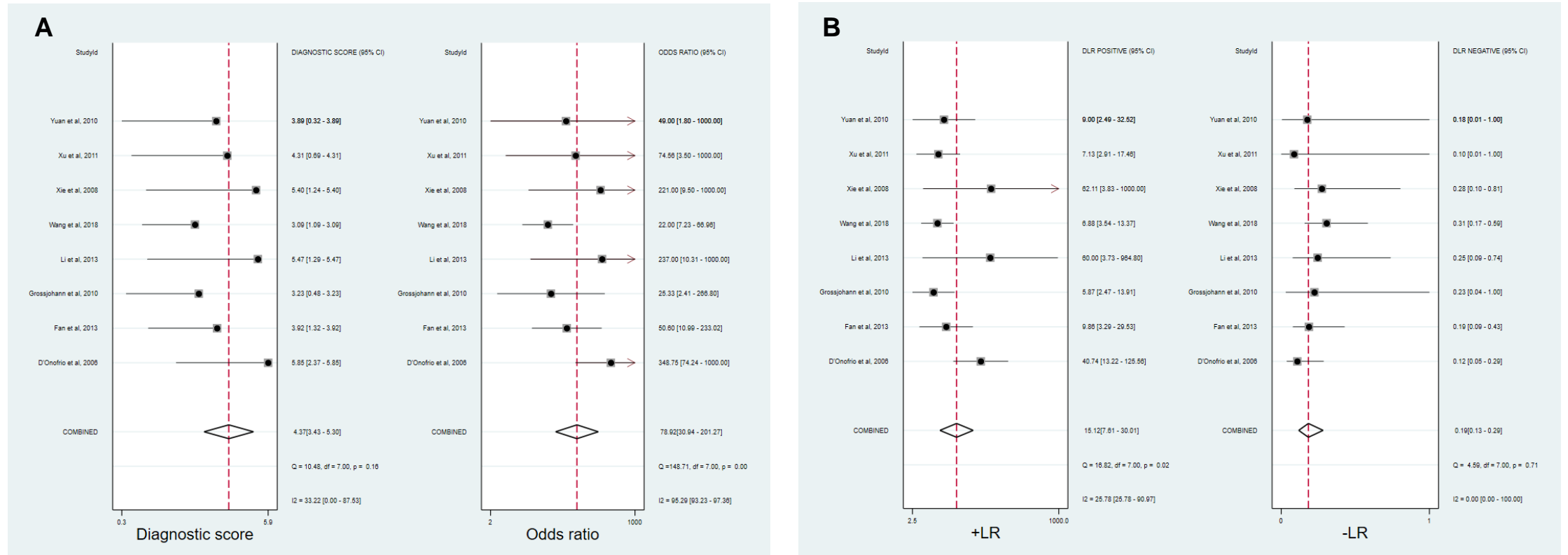
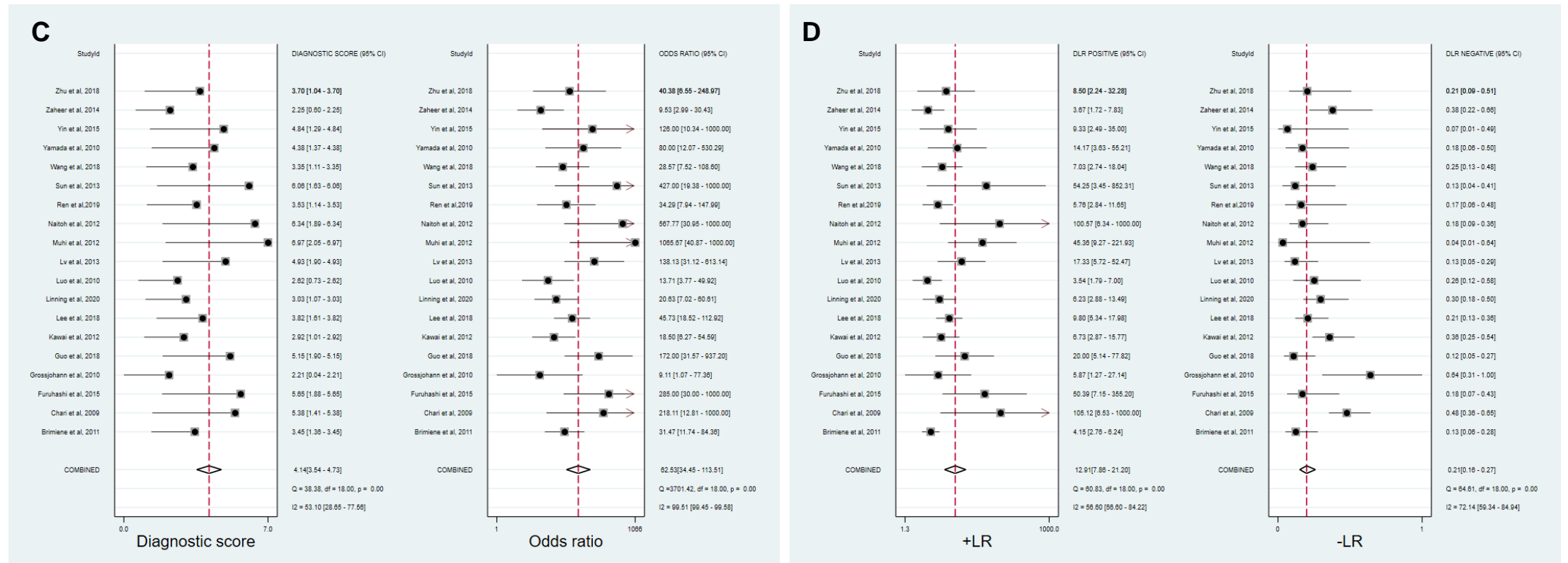


Supplementary Figure 1

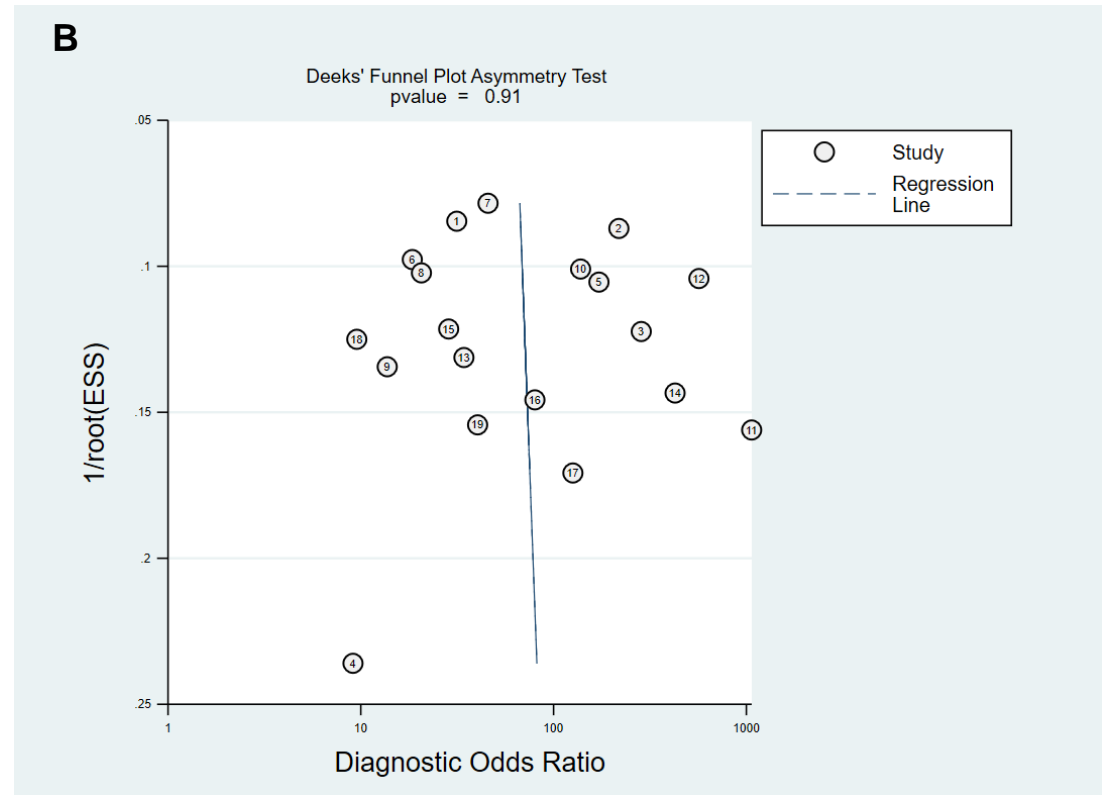
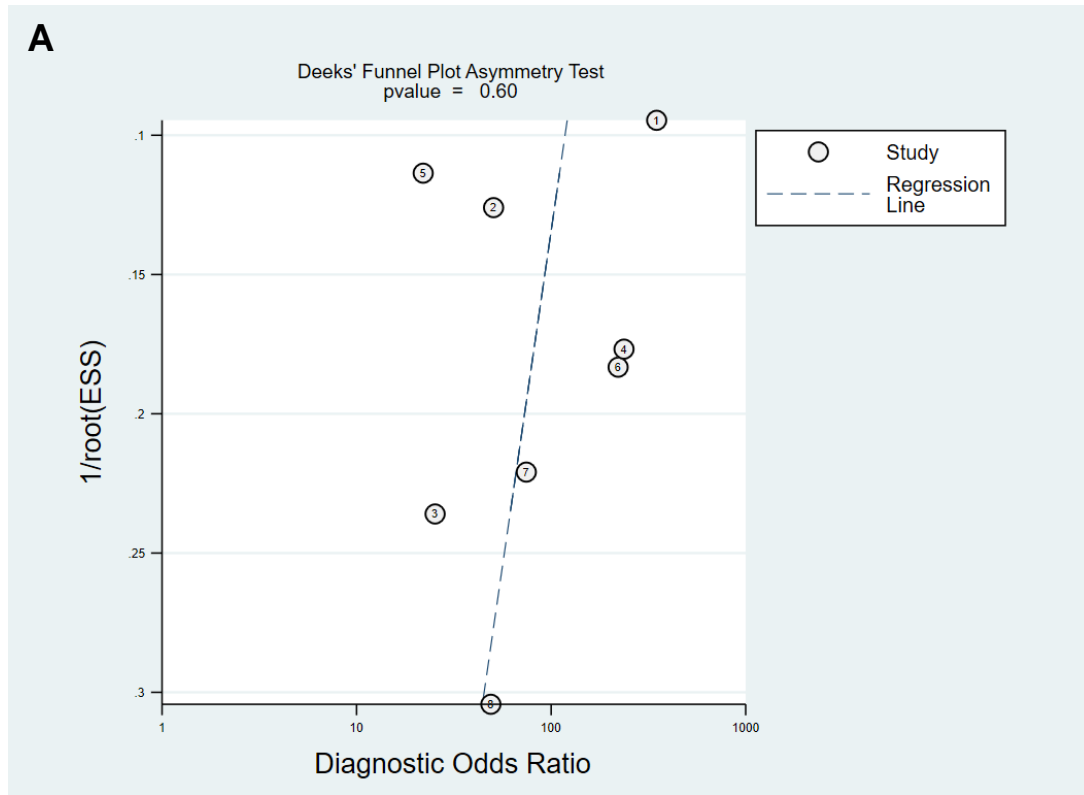


Supplementary Figure 1



Supplementary Figure 1: Coupled forest plots of the +LR, -LR, and DOR for the differential diagnosis of MFP from PDAC on CEUS (A, B) and CECT (C, D). CECT: Contrast-enhanced computed tomography; CEUS: Contrast-enhanced ultrasound; +LR: Positive likelihood ratio; -LR: Negative likelihood ratio; DOR: Diagnostic odds ratio; MFP: Mass-form pancreatitis; PDAC: Pancreatic ductal adenocarcinoma.

Supplementary Figure 2



Supplementary Figure 2: Deek's funnel plots of the public bias for the differential diagnosis of MFP from PDAC on CEUS (A) and CECT (B). CECT: Contrast-enhanced computed tomography; CEUS: Contrast-enhanced ultrasound; MFP: Mass-form pancreatitis; PDAC: Pancreatic ductal adenocarcinoma.