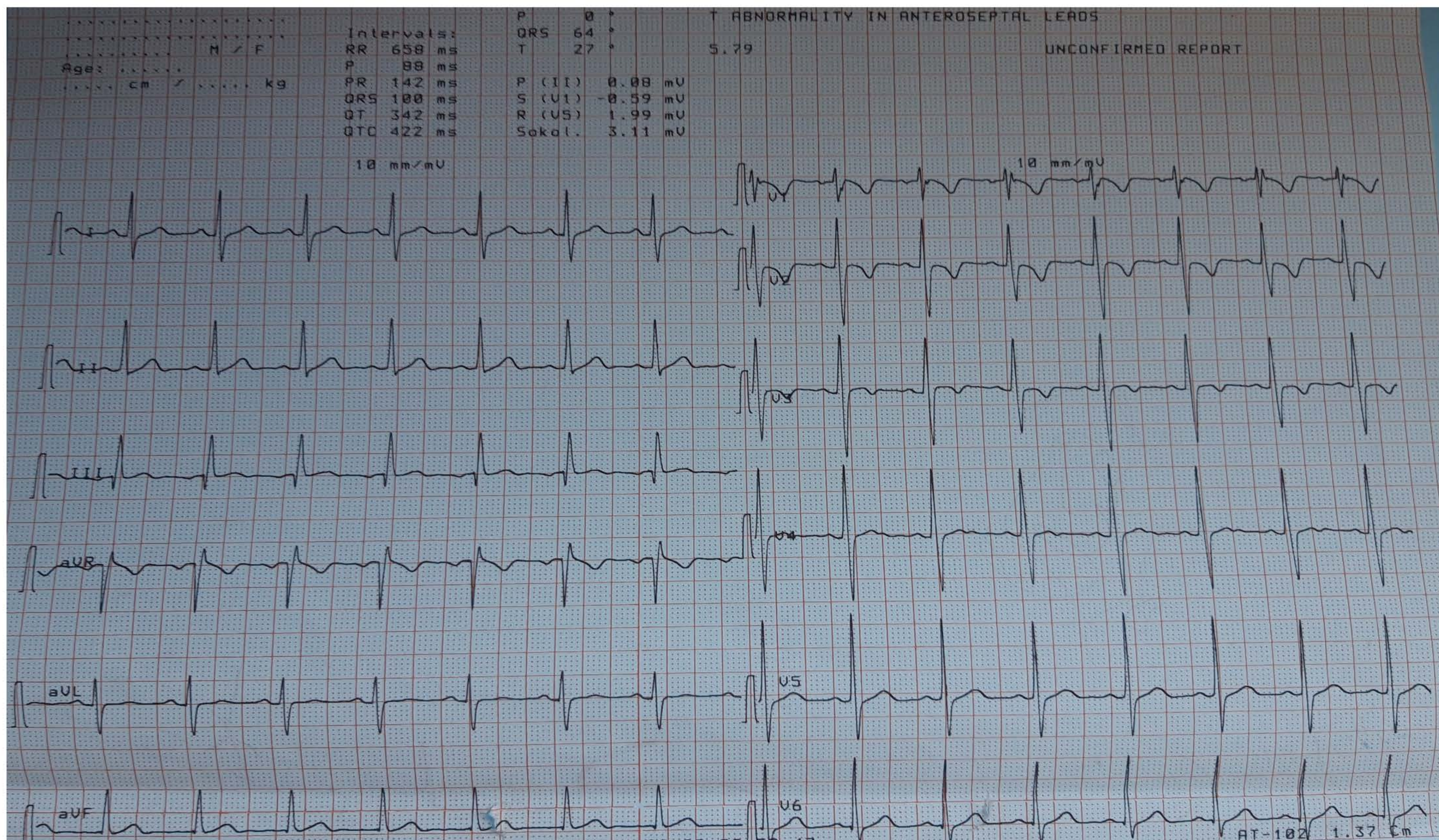
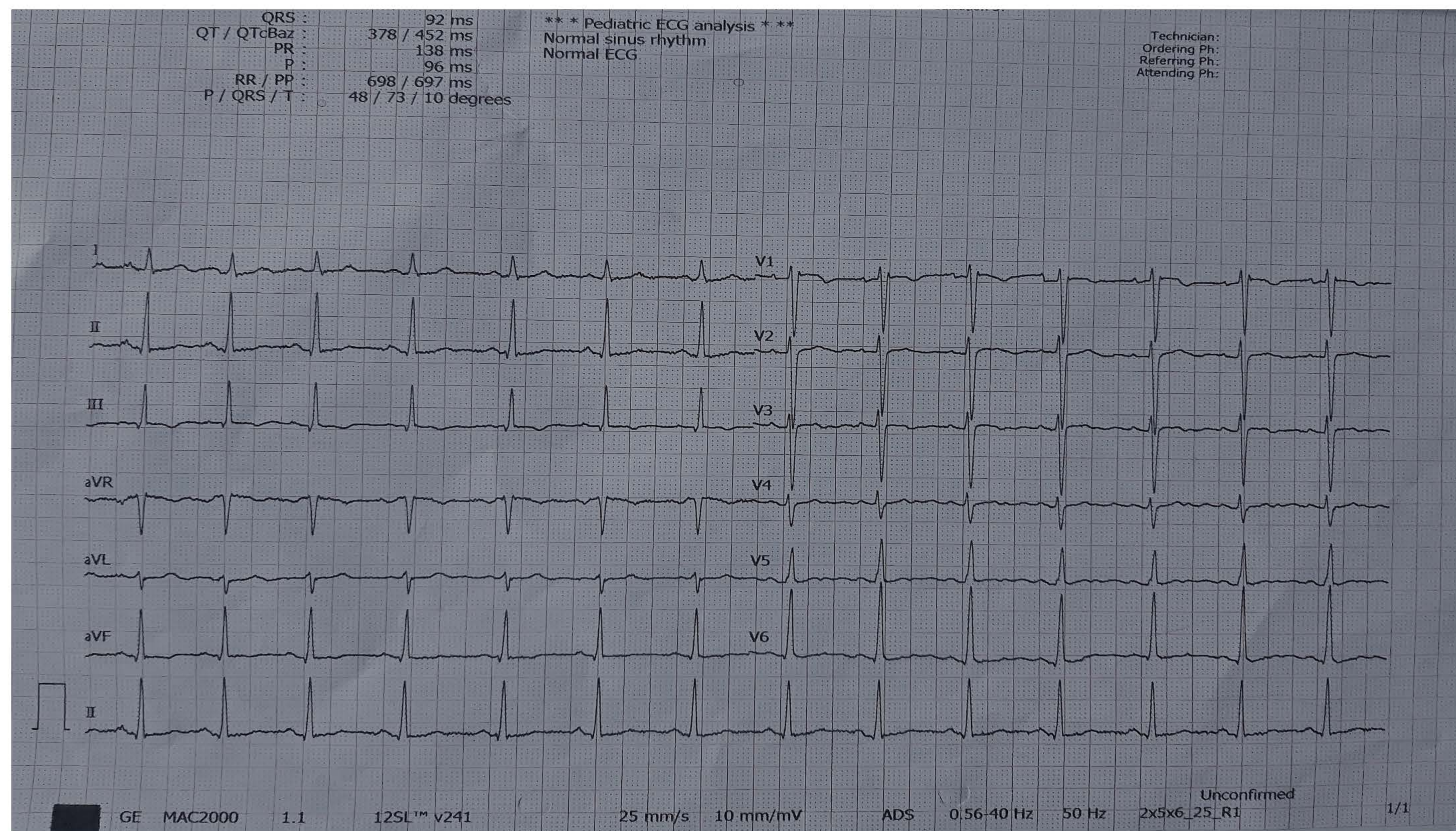


(a)



(b)



Supplemental Digital Content 1.

Electrocardiogram with T-wave inversion in (a) case 1 and (b) case 2.