

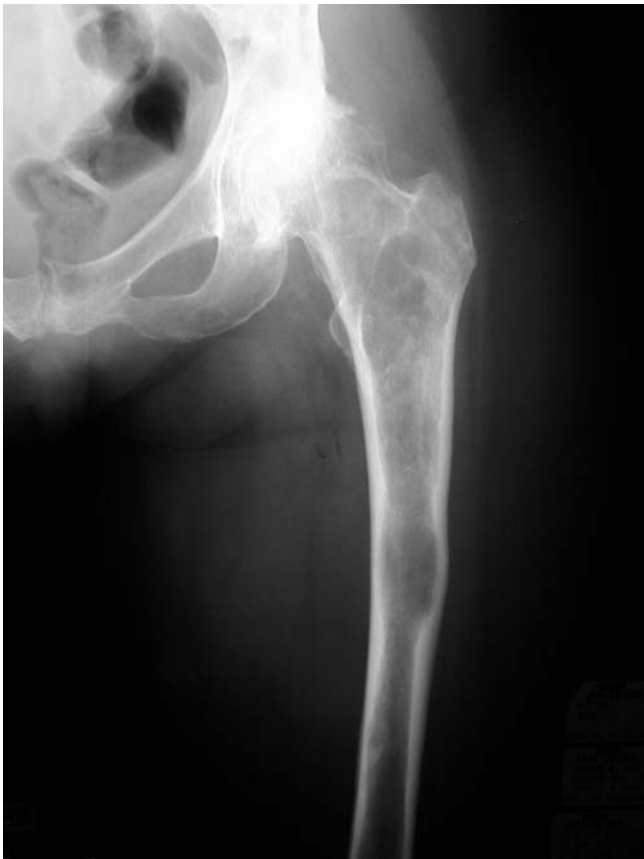

Fig. E1-A  
Preoperative radiograph of a sixty-five-year-old woman (Case 1) with monostotic fibrous dysplasia of the proximal part of the femur and a resultant varus deformity.

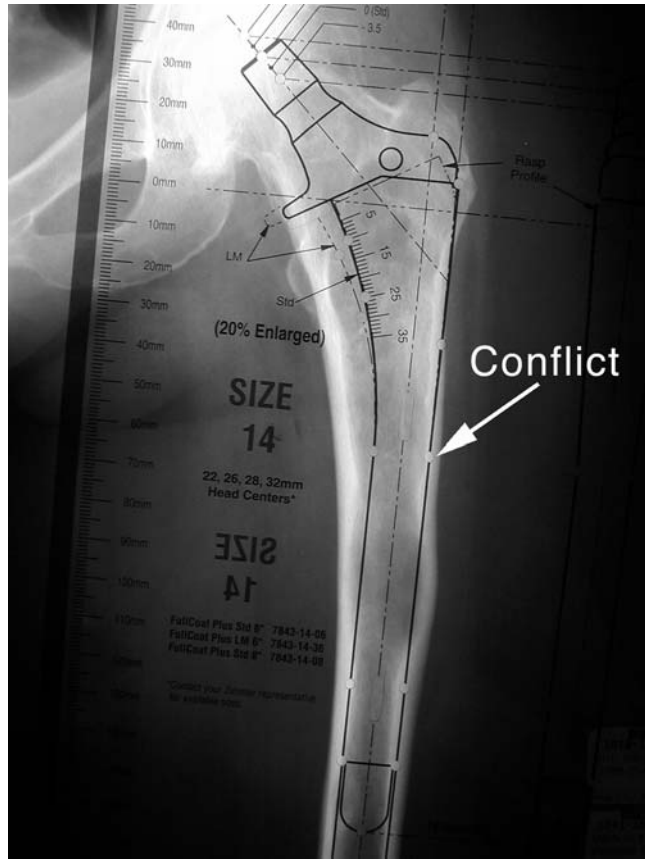


Fig. E1-B  
With a template in place, a mismatch is noted between the shape of the proximal part of the femur and the proposed implant to be used. The extended trochanteric osteotomy will need to be made to this level.

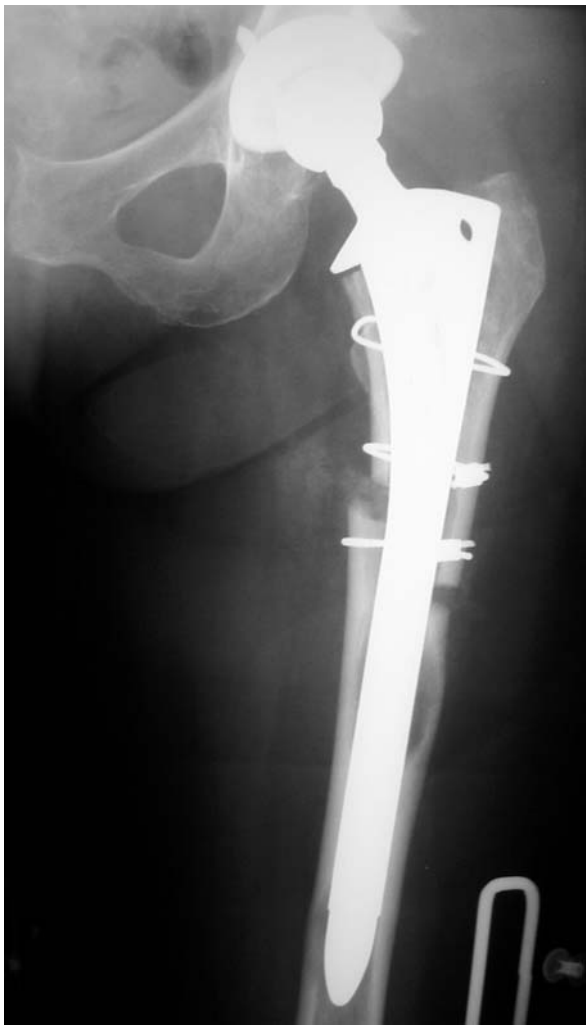

Fig. E1-C  
Postoperative radiograph. A second osteotomy of the medial cortex was required for full deformity correction.

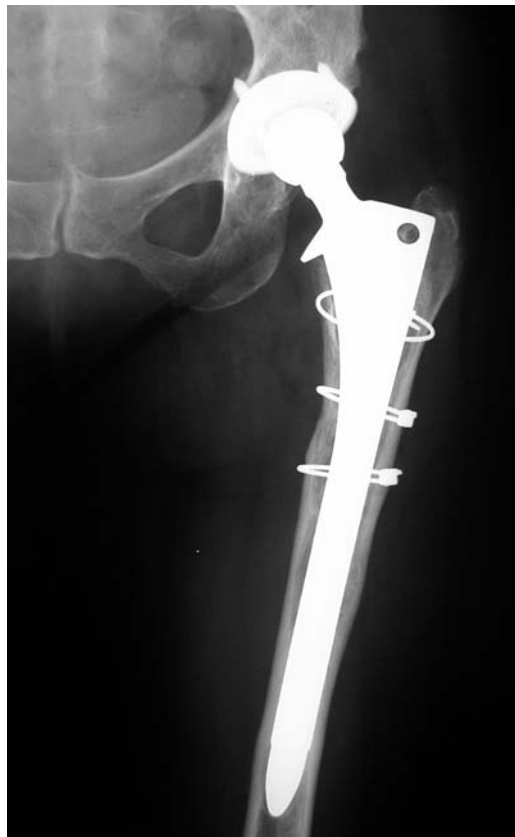

Fig. E1-D  
At sixty-eight months, the osteotomy had healed and the femoral component was osseointegrated.