

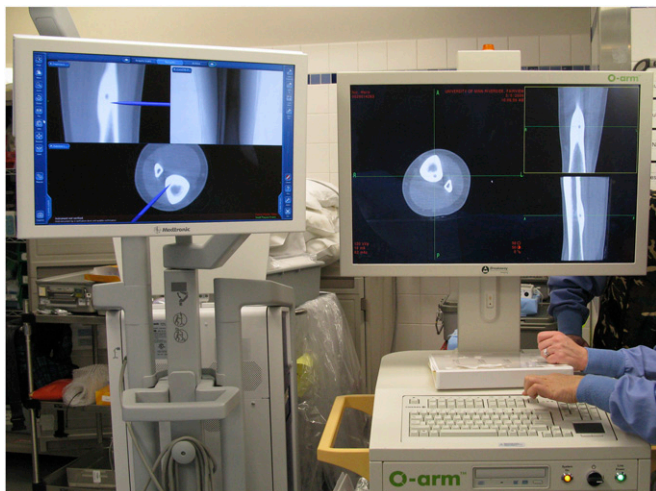Fig. E-1

Intraoperative photograph of the O-Arm monitor on the right and StealthStation monitor on the left showing an osteoid osteoma in the tibial diaphysis on each monitor. (The patient is not the same as the one in Figure 2.)

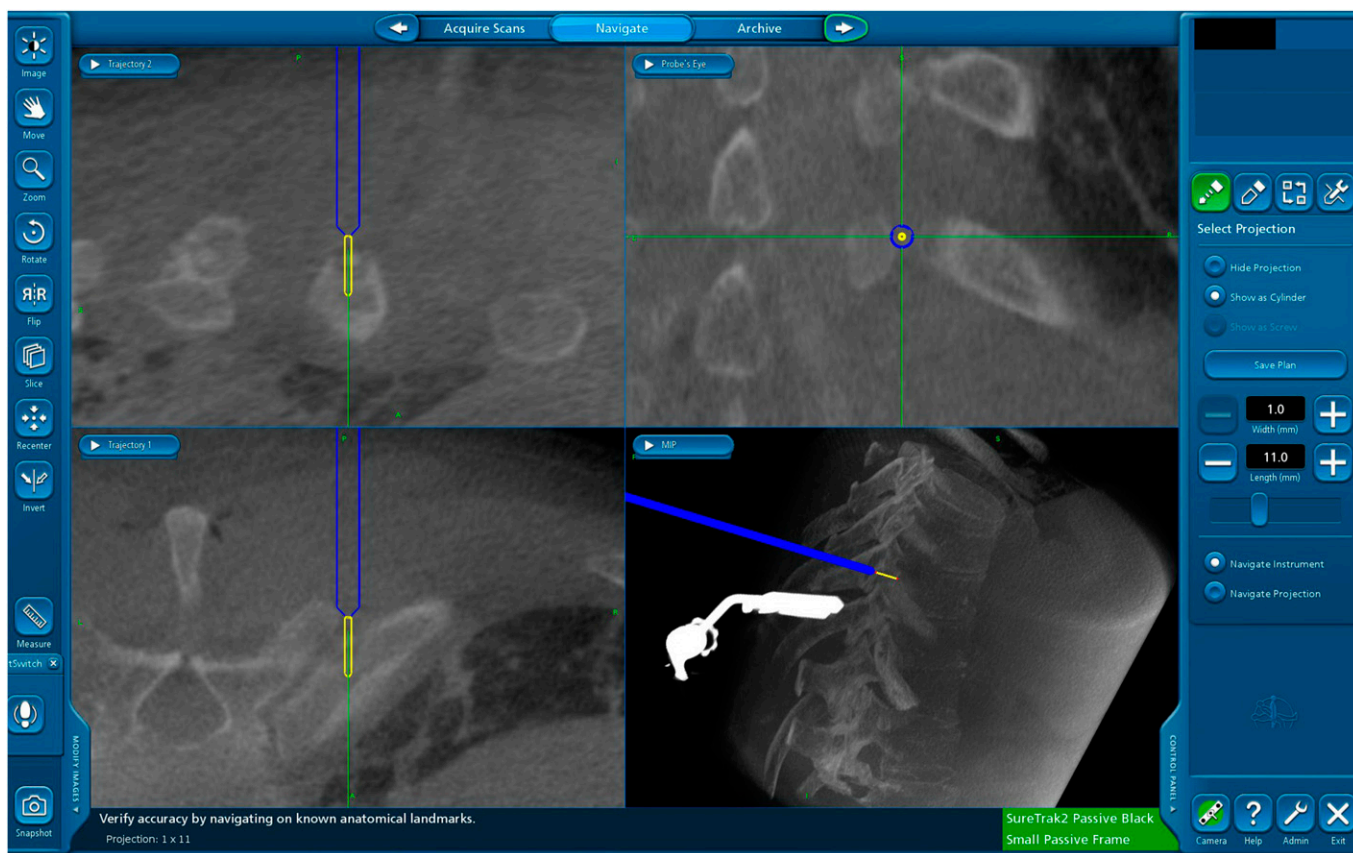


Fig. E-2

StealthStation screenshot of an osteoid osteoma in the right T10 costovertebral junction.

TABLE E-1 Number of RF Ablation Probes Required			
Group	No. (%) of Patients in Group		
	1 Probe	2 Probes	3 Probes
1	15 (65)	7 (30)	1 (4)
2	7 (100)	0 (0)	0 (0)
3	30 (83)	6 (17)	0 (0)