

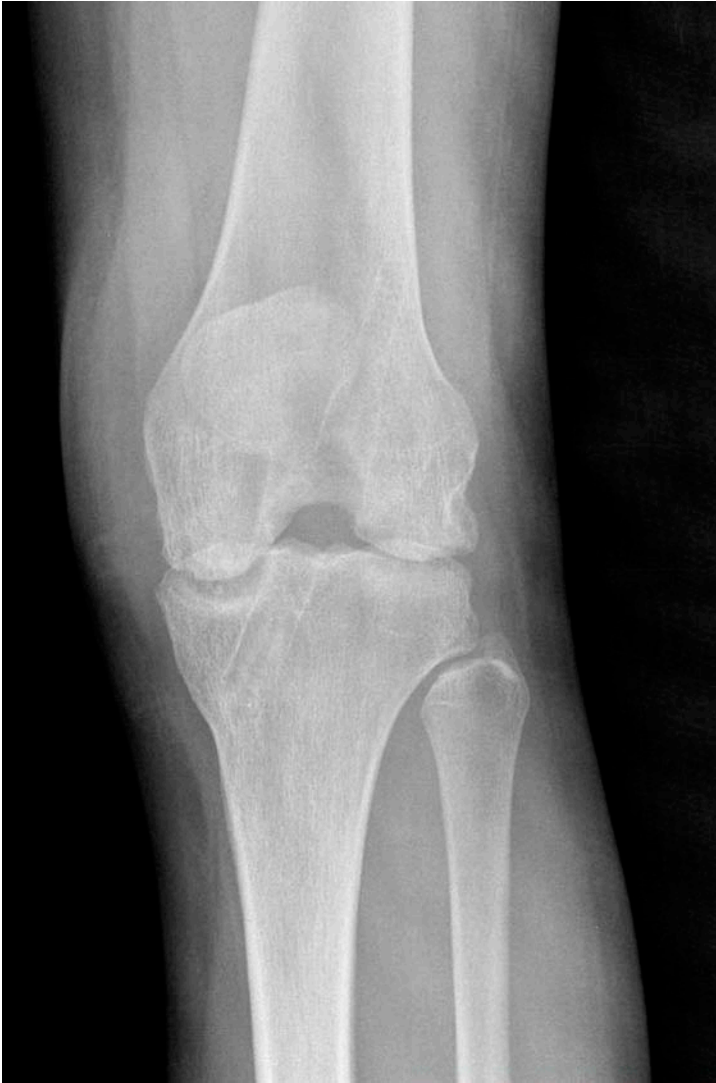

Fig. E-1A

**Figs. E-1A and E-1B** Case 12, a seventeen-year-old girl. **Fig. E-1A** Anteroposterior radiograph made before proximal tibial osteotomy.

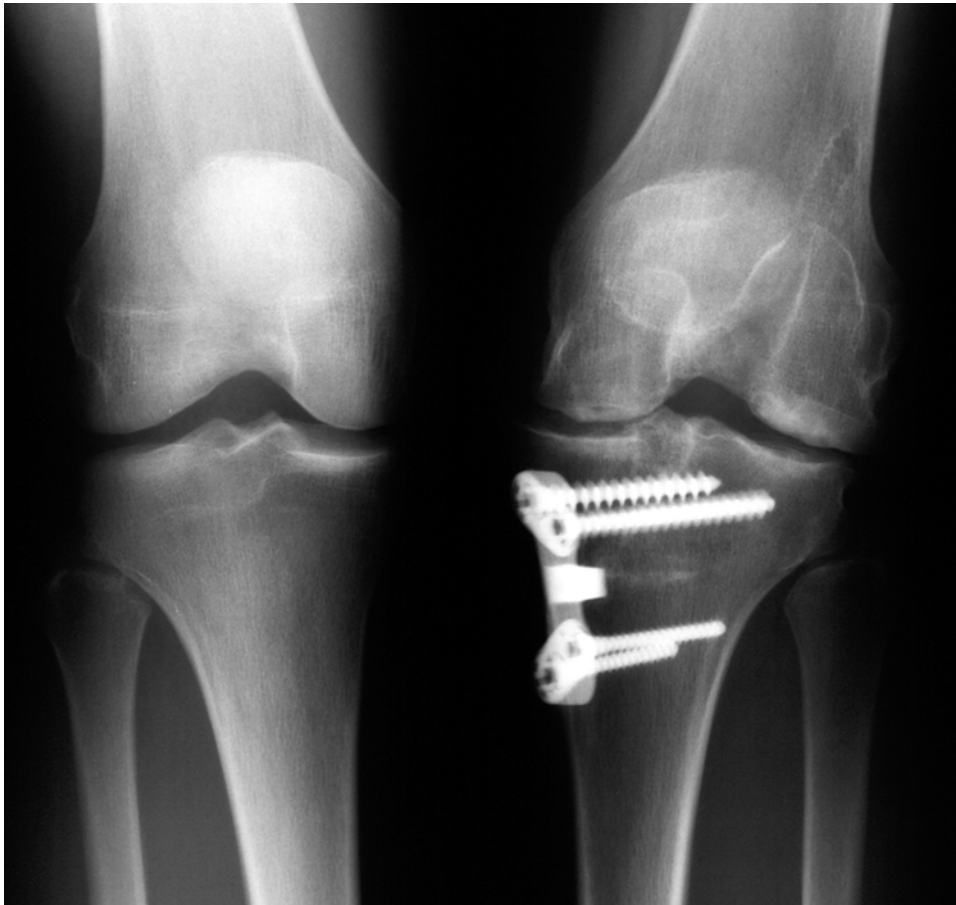


Fig. E-1B

Anteroposterior radiograph made after proximal tibial osteotomy and osteochondral allografting of the medial and lateral femoral condyles, performed fourteen months after the use of an intra-articular pain pump before evaluation at our center. The patient continued to have severe symptoms with daily activities.

TABLE E-1 Demographic Data and Data on Index Procedure

Case	Age at Time of Index Procedure (yr)	Sex	Index Procedure*	Pain Pump Volume, Infusion Rate†	No. of Hours Pain Pump Used Postop.	Epinephrine Included	Intra-Articular Bolus Injection	Condition of Articular Cartilage at Time of Index Procedure
1	24	F	ACLR posterior tibialis allograft	270 mL, infusion rate NA	48	No	No	All normal
2	21	F	Proximal-distal extensor mechanism realignment, Fulkerson tibial tubercle osteotomy, lateral release	120 mL, infusion rate NA	96	No	No	Small area fissuring undersurface patella and trochlea, other surfaces normal
3	14	F	ACLR, graft unknown	100 mL, infusion rate NA	48	Yes	No	All normal
4	41	F	ACLR STG autograft, subtotal MM, LM	NA	48	No	Yes	All normal
5	19	F	Arthroscopy	270 mL, 5 mL/hr	48	No	No	Small area fissuring undersurface patella, other surfaces normal
6	15	F	ACLR STG autograft	200 mL, 2 mL/hr	72	Yes	Yes	All normal
7	42	M	ACLR STG autograft	250 mL, infusion rate NA	48	No	No	All normal
8	20	M	ACLR B-PT-B autograft, partial MM, LM	100 mL, 2 mL/hr	48	Yes	No	Small area fissuring medial femoral condyle, other surfaces normal
9	22	F	ACLR B-PT-B autograft	90 mL, infusion rate NA	48	No	No	All normal
10	16	F	ACLR STG autograft	200 mL, 2 mL/hr	48	Yes	Yes	All normal
11	17	F	ACLR STG autograft, total MM	100 mL, infusion rate NA	48	Yes	No	All normal
12	17	F	ACLR STG autograft, lateral meniscal repair	200 mL, 2 mL/hr	48	Yes	No	All normal
13	22	F	ACLR STG autograft	200 mL, infusion rate NA	48	Yes	Yes	All normal
14	38	F	Medial meniscal repair	120 mL, 2 mL/hr	48	No	No	All normal
15	33	M	ACLR B-PT-B autograft	270 mL, 5 mL/hr	72	No	No	Small area chondromalacia patella, other surfaces normal
16	24	F	ACLR anterior tibialis allograft	270 mL, 5 mL/hr	72	No	Yes	All normal
17	16	F	ACLR STG autograft, medial meniscal repair	100 mL, 2 mL/hr	120	Yes	Yes	All normal
18	22	F	ACLR STG autograft	100 mL, 2 mL/hr	120	Yes	No	All normal

19	25	F	ACLR STG autograft	100 mL, 2 mL/hr	48	Yes	No	All normal
20	22	F	ACLR B-PT-B autograft	110 mL, 2 mL/hr	48	No	No	All normal
21	18	F	ACLR STG autograft	100 mL, infusion rate NA	48	Yes	No	All normal

\*ACLR = anterior cruciate ligament reconstruction, B-PT-B = bone-patellar tendon-bone, LM = lateral meniscectomy, MM = medial meniscectomy, STG = semitendinosus-gracilis. †NA = not available.

TABLE E-2 Condition of the Menisci and Effect on Articular Cartilage Surfaces

Condition of Menisci at Index Operation*	No. Knees With Abnormal Articular Cartilage Surfaces		
	Medial Tibiofemoral	Lateral Tibiofemoral	Patellofemoral
Both intact (14 knees)*	9	4	12
Lateral meniscal repair (1 knee)	1	1	1
Medial meniscal repair (2 knees)	2	0	2
Total MM (1 knee)	1	0	1
Partial MM (1 knee)	1	0	1
Partial MM, LM (1 knee)	1	1	1
Partial MM, LM (1 knee)	1	0	0

\*LM = lateral meniscectomy, MM = medial meniscectomy.