

Appendix

Relationship Between Angular Deformity, Measured with Radiographic Analysis, and Rotational Restriction

Methods

We measured the angular deformity on plain anteroposterior and lateral radiographs by superimposing the affected (ipsilateral) proximal aspect of the radius and ulna onto the corresponding part of the mirror image of the contralateral, unaffected radius and ulna (Fig. E-1). The relationship between angular deformities measured by radiographic analysis and forearm rotational range of motion was analyzed using the Pearson correlation coefficient. The relationship between the deformity measured in 3-dimensional (3-D) analysis and in the radiographic analysis was also analyzed using the Pearson correlation coefficient.

Results

In the RE group, extension deformity of the radius had a significant negative correlation with pronation range of motion ($R = -0.61$, $p = 0.013$); however, valgus deformity of the ulna did not show a correlation with supination range of motion (Table E-1). Patients with $>10^\circ$ extension deformity of the radius on radiographic analysis showed pronation restriction.

The relationship between the deformity measured using 3-D analysis and radiographic analysis is shown in Table E-2. The correlation of valgus deformity of the ulna measured using 3-D analysis and radiographic analysis was relatively small. It was difficult to obtain true anteroposterior radiographs with good reproducibility because patients had deformity and forearm rotational restriction.

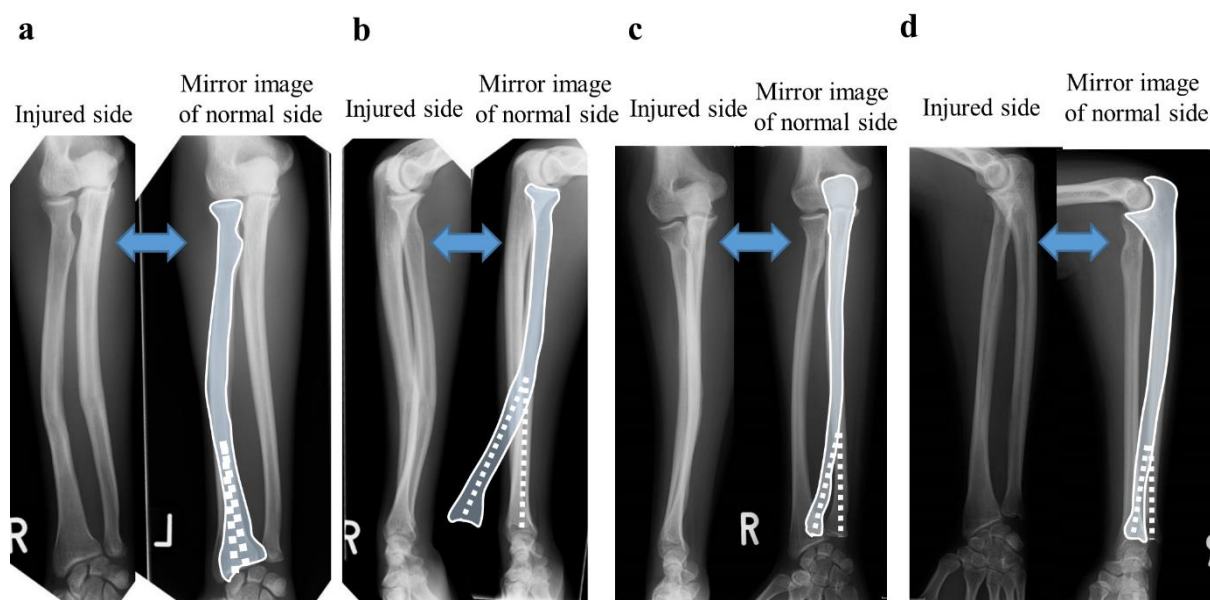


Fig. E-1

Anteroposterior and lateral radiographs of the radius and ulna. **Figs. E-1A and E-1B** The silhouette of the proximal part of the malunited radius in the anteroposterior (**Fig. E-1A**) and lateral (**Fig. E-1B**) radiographs was superimposed onto the corresponding region of the mirror image of the normal radius. The angle between the 2 dotted lines represents the angular deformity. **Figs. E-1C and E-1D** The same method was applied to the ulna.

TABLE E-1 Relationship Between the Angular Deformity According to Radiographic Analysis and Range of Motion for the 16 Patients in the RE Group

	Pronation Range of Motion*		Supination Range of Motion*	
	R Value	P Value	R Value	P Value
Radius†				
Extension (lateral radiograph)	-0.61	0.013	-0.22	0.41
Valgus (+)-varus (-) (AP radiograph)	0.02	0.939	0.23	0.396
Ulna†‡				
Extension (+)-flexion (-) (lateral radiograph)	0.08	0.796	-0.30	0.343
Valgus (+)-varus (-) (AP radiograph)	-0.36	0.254	-0.43	0.16

*The Pearson correlation coefficient (R value) was calculated using a parametric statistical test. †AP = anteroposterior.

‡Ulnar deformity was found in only 12 of 16 patients.

TABLE E-2 Relationship of Deformity Between 3-D Analysis and Radiographic Analysis for the 16 Patients in the RE Group

	R Value*	P Value
Radius†		
Extension deformity (lateral radiograph)	0.93	<0.001
Valgus (+)-varus (-) (AP radiograph)	0.93	<0.001
Ulna†‡		
Extension (+)-flexion (-) (lateral radiograph)	0.81	0.001
Valgus (+)-varus (-) (AP radiograph)	0.61	0.033

*The Pearson correlation coefficient (R value) was calculated using a parametric statistical test. †AP = anteroposterior.

‡Ulnar deformity was found in only 12 of 16 patients,