

The following content was supplied by the authors as supporting material and has not been copy-edited or verified by JBJS.

Appendix:

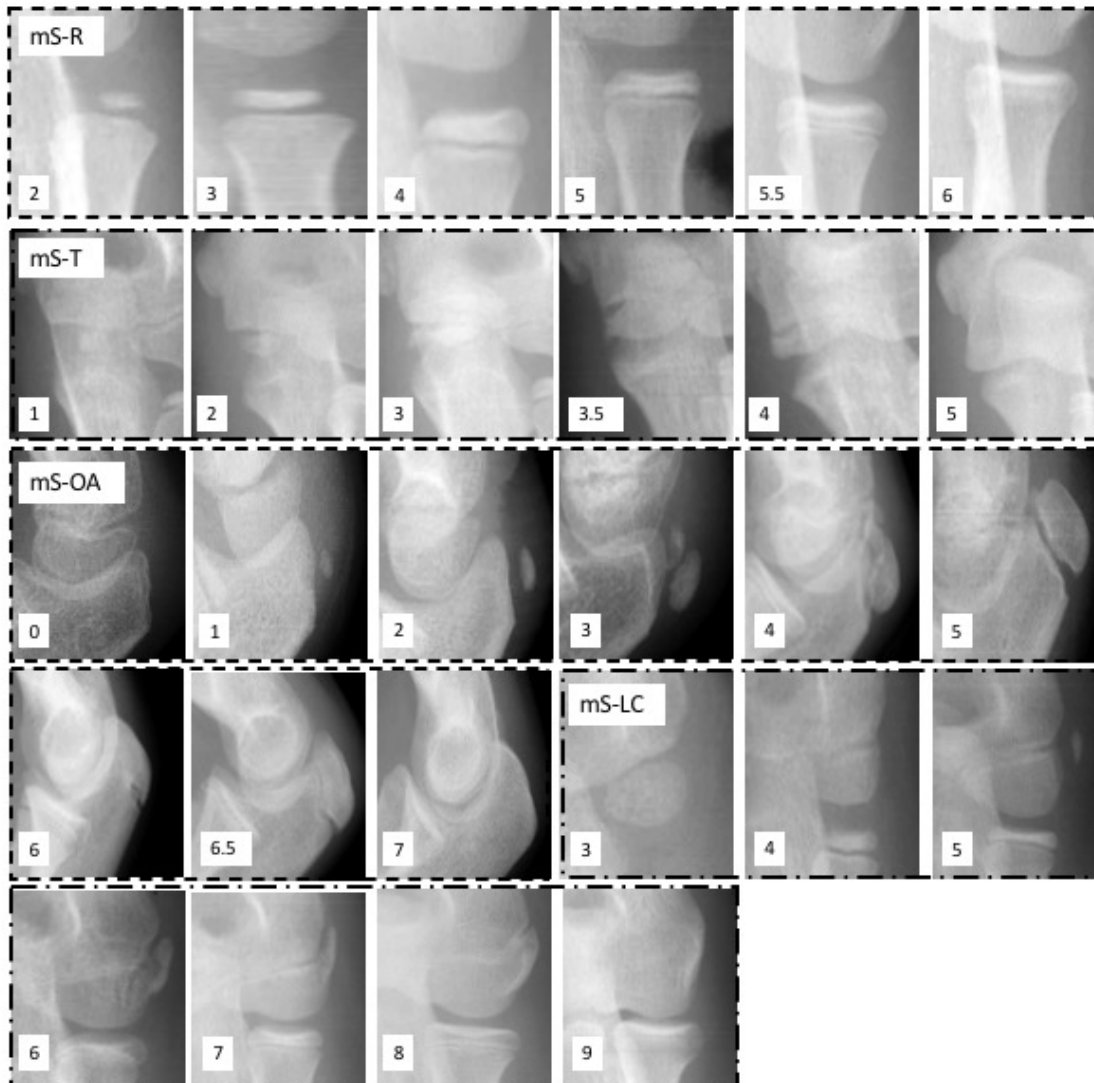


Figure 1: The parameters within the Modified Sauvegrain system, with inclusion of only stages seen in the peripubertal range.

mS-R: the modified Sauvegrain method of scoring the development of the radial head. 2 = ovoid ossification is under 50% of total metaphysis length. 3 = elongates to between 50-75% of metaphysis length. 4 = elongates to between 76-100% of metaphysis length. 5 = medial edge of

the ossification begins to curl towards the metaphysis. 5.5 = the lateral and medial edge of the ossification curl towards the metaphysis. 6 = complete fusion of the radial head.

mS-T: the modified Sauvegrain method of scoring the development of the trochlea. 1 = appearance of small circular ossification that is no more than two times as long as it is tall. 2 = elongation of ossification to being more than two times as long as it is tall. 3 = ossification approaches capitellum and increases width. 3.5 = the lateral aspect of the ossification develops a point and comes in contact with the capitellum. 4 = fusion with the capitellum begins. 5 = complete fusion with capitellum and humerus.

mS-OA: the modified Sauvegrain method of scoring the development of the olecranon apophysis. 0 = complete absence of any ossification. 1 = appearance of small, round ossification center. 2 = progression to a single, oblong ossification. 3 = second ossification center appears. 4 = the two ossification centers overlap. 5 = fusion of the two ossification centers into a single rectangular appearing center. 6 = center rounding and advancement past articular surface. 6.5 = apophysis begins to fuse. 7 = complete apophysis fusion.

mS-LC: the modified Sauvegrain method of scoring the development of the lateral condyle. 3 = ossification becomes more rectangular and begins to fill into humeral groove. 4 = ossification center becomes more triangular to mimic corresponding groove in humerus. 5 = second ossification center appears and is separated from the initial ossification center by a space larger than the width of the second ossification center. 6 = the second ossification center enlarges toward to primary center and approximates the rest of the capitellum. 7 = the two ossifications fuse. 8 = the ossification center partially fuses to the humerus. 9 = complete fusion.

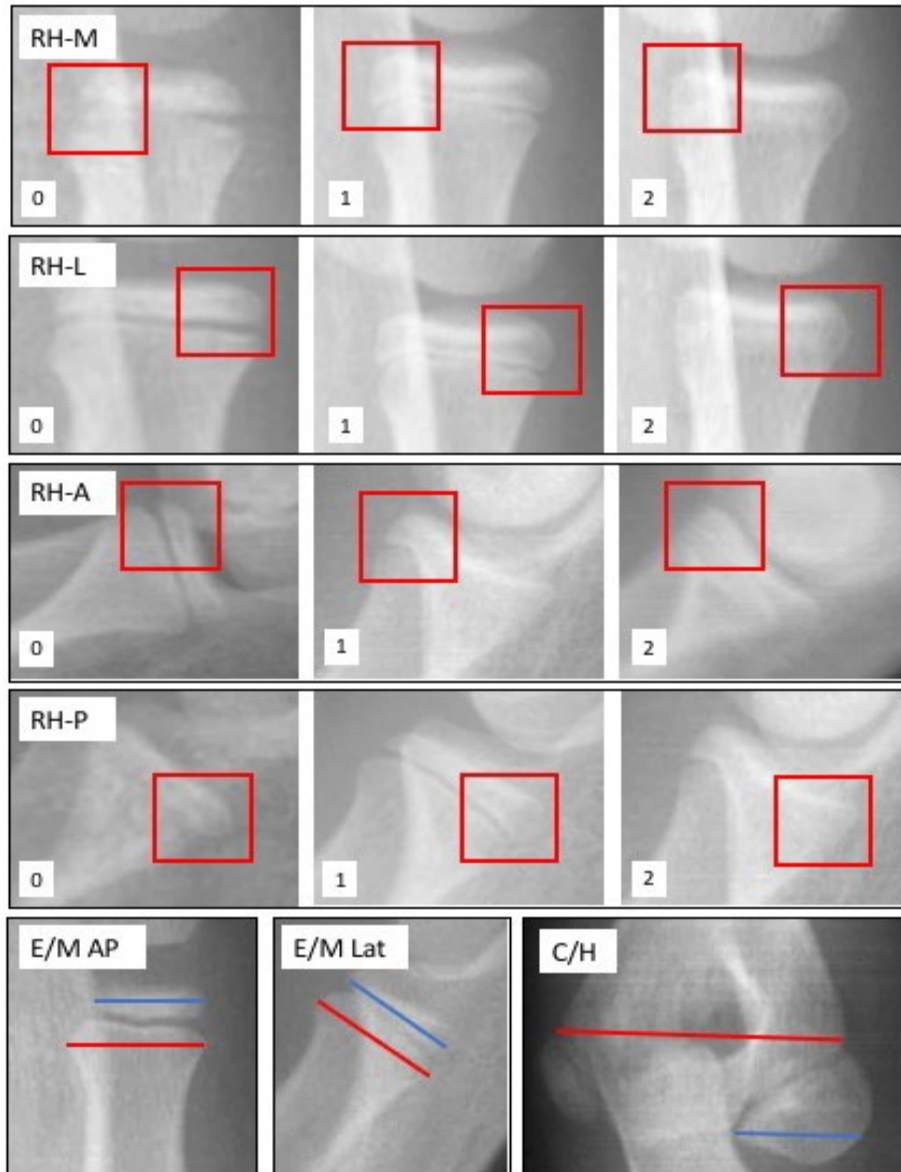


Figure 2: The novel parameters included in analysis

RH-M: Medial capping of the radial head epiphysis. 0 = Absent, blunted medial margin of the radial head epiphysis with no downward peak or projection. 1 = Partial, the medial margin of the radial head epiphysis extends as a downward projection at the medial margin of the radial head epiphysis with or without distinct peak. 2 = Complete, the medial margin is congruent with the medial margin of the metaphysis with evidence of fusion due to lack of radiolucent gap between epiphysis and metaphysis

RH-L: Lateral capping of the radial head epiphysis. 0 = Absent, blunted medial margin of the radial head epiphysis with no downward peak or projection. 1 = Partial, the lateral margin of the radial head epiphysis extends as a downward projection at the lateral margin of the radial head epiphysis with or without distinct peak. 2 = Complete, the lateral margin is congruent with the lateral margin of the metaphysis with evidence of fusion due to lack of radiolucent gap between epiphysis and metaphysis

RH-A: Anterior capping of the radial head epiphysis. 0 = Absent, blunted anterior margin of the radial head epiphysis with no downward peak or projection. 1 = Partial, the anterior margin of the radial head epiphysis extends as a downward projection at the anterior margin of the radial head epiphysis with or without distinct peak. 2 = Complete, the anterior margin is congruent with the anterior margin of the metaphysis with evidence of fusion due to lack of radiolucent gap between epiphysis and metaphysis.

RH-P: Posterior capping of the radial head epiphysis. 0 = Absent, blunted posterior margin of the radial head epiphysis with no downward peak or projection. 1 = Partial, the posterior margin of the radial head epiphysis extends as a downward projection at the posterior margin of the radial head epiphysis with or without distinct peak. 2 = Complete, the posterior margin is congruent with the posterior margin of the metaphysis with evidence of fusion due to lack of radiolucent gap between epiphysis and metaphysis.

E/M AP: Epiphyseal to metaphyseal width ratio on AP radiograph. Measure the greatest width of the proximal radial metaphysis (M). Next, measure the greatest width of the proximal radial epiphysis in a line parallel to the metaphyseal line (E). Divide the epiphyseal width by the metaphyseal width.

E/M Lat: Epiphyseal to metaphyseal width ratio on lateral radiograph. Measure the greatest width of the proximal radial metaphysis (M). Next, measure the greatest width of the proximal radial epiphysis in a line parallel to the metaphyseal line (E). Divide the epiphyseal width by the metaphyseal width.

C/H: Capitellum to humerus ratio on AP radiograph. Measure the greatest width of the humerus between the two condyles not including the epicondyles (H). Next, measuring the greatest width of the capitellum in a line parallel to the humerus (C). Divide the capitellum width by the humerus width.