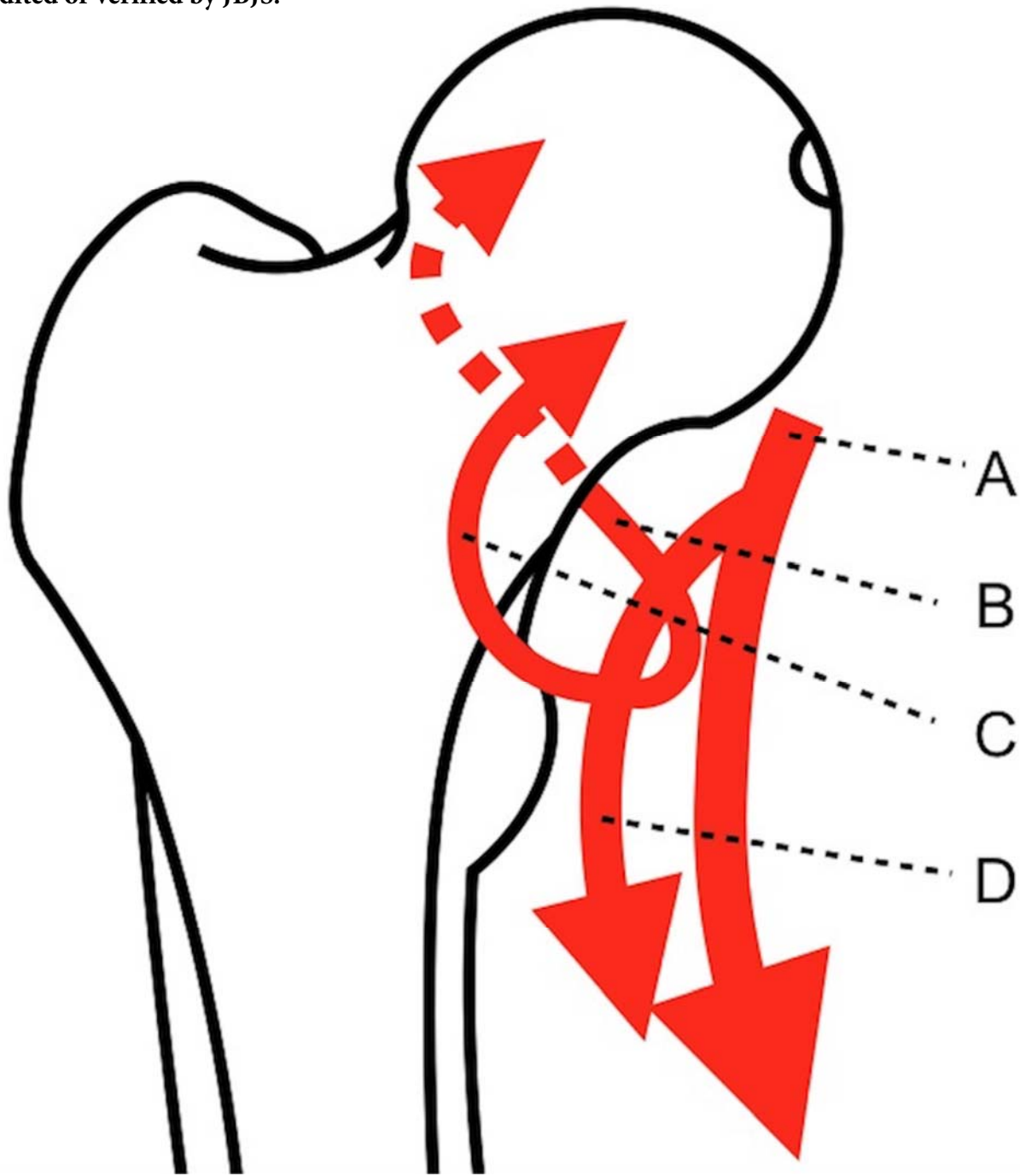


The following content was supplied by the authors as supporting material and has not been copy-edited or verified by JBJS.



Simplified vascular supply of the femoral head (anterior view). A - femoral artery. B - medial circumflex femoral artery and ascending branches. C - lateral circumflex femoral artery. D - deep femoral artery.