

Appendix E-1

TABLE E-1 Baseline Variables and Clinical Score in 1 Patient Who Declined Radiographic Examinations and 2 Patients Who Underwent Treatment with Double-Bundle Technique**†

Variable	Patient 1	Patient 2	Patient 3
Constant score (<i>points</i>)	90	98	100
ASES score (<i>points</i>)	100	100	100
Sex	F	M	M
Age* (<i>yr</i>)	52	35	41
Side	R	L	L
Injury mechanism	Motor-vehicle accident	Sport	Motor-vehicle accident
Rockwood type	V	V	V
CCD ratio (%)	NA	-6.4	-6.0
Posterior displacement	NA	-	-
Implant pullout	NA	-	-
Ossification	NA	+	+
Osteoarthritis	NA	+	+

*ASES = American Shoulder and Elbow Surgeons, and NA = not available. †Patient 1 declined radiographic examinations, and Patients 2 and 3 had treatment with the double-bundle technique.

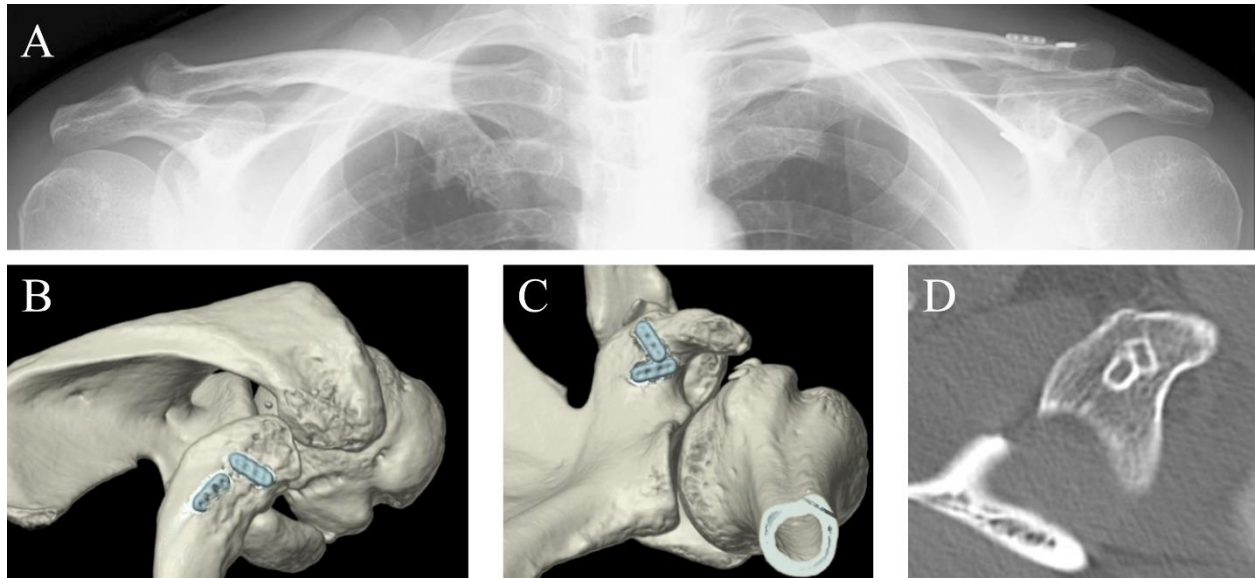


Fig. E1

Figs. E1-A through E1-D Case 2. **Figs. E1-A** Radiograph showing both shoulders. **Fig. E1-B** 3D reconstructed CT image showing 2 ENDOBUTTONS on the right clavicle. **Fig. E1-C** 3D reconstructed CT image showing 2 ENDOBUTTONS on the undersurface of the coracoid base. **Fig. E1-D** Axial CT image showing 2 coracoid tunnels located very close to each other.