

FIG 1

A 24 yo with an
open posterior VS
right , an APC 2
left (61C2.3)
and a right
transverse
acetabular
fracture (62B3.2b)
Trauma Bay X-Ray

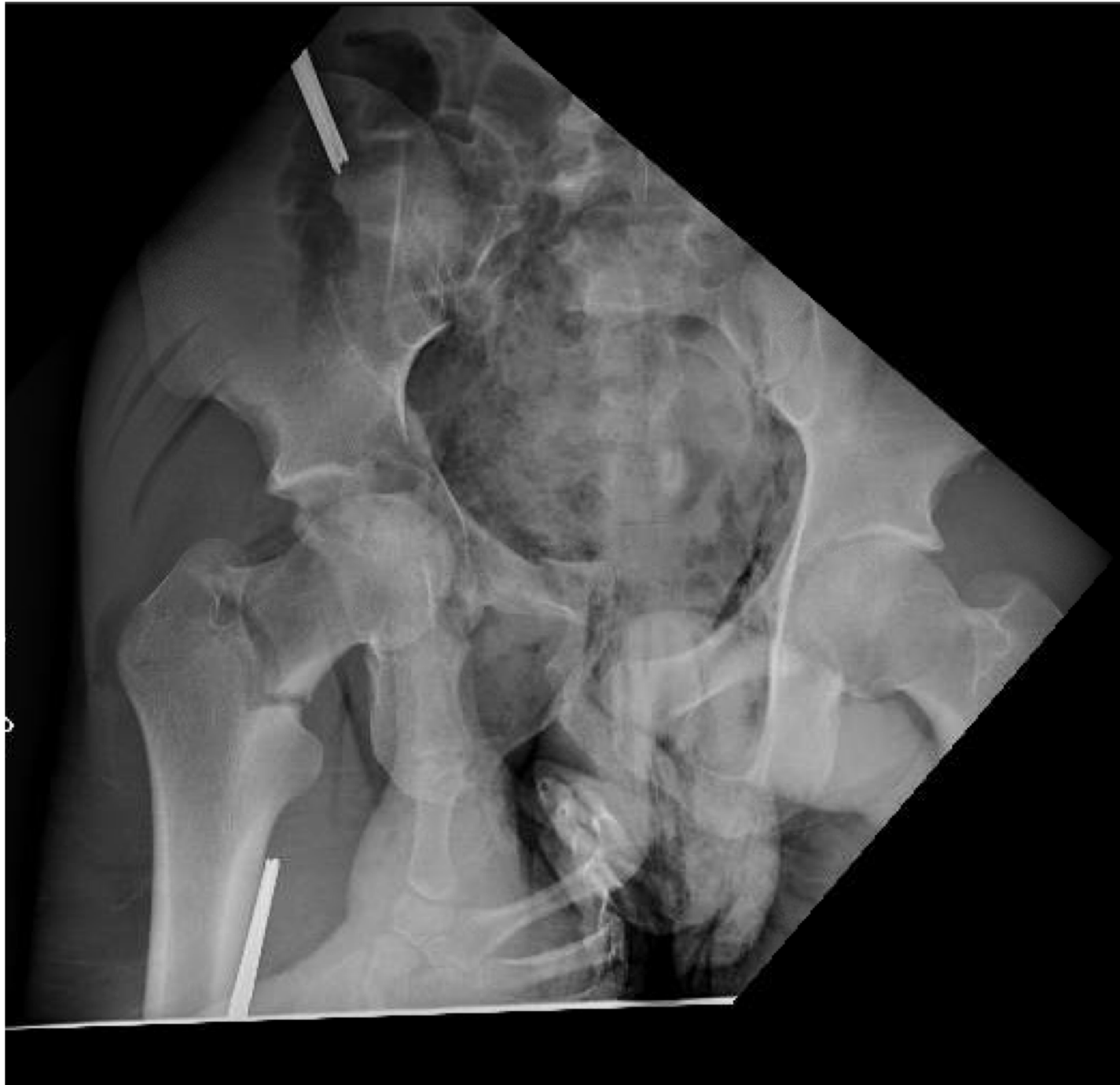

FIG 2 Intra operative X-ray after temporary fixation with an anterior external fixator

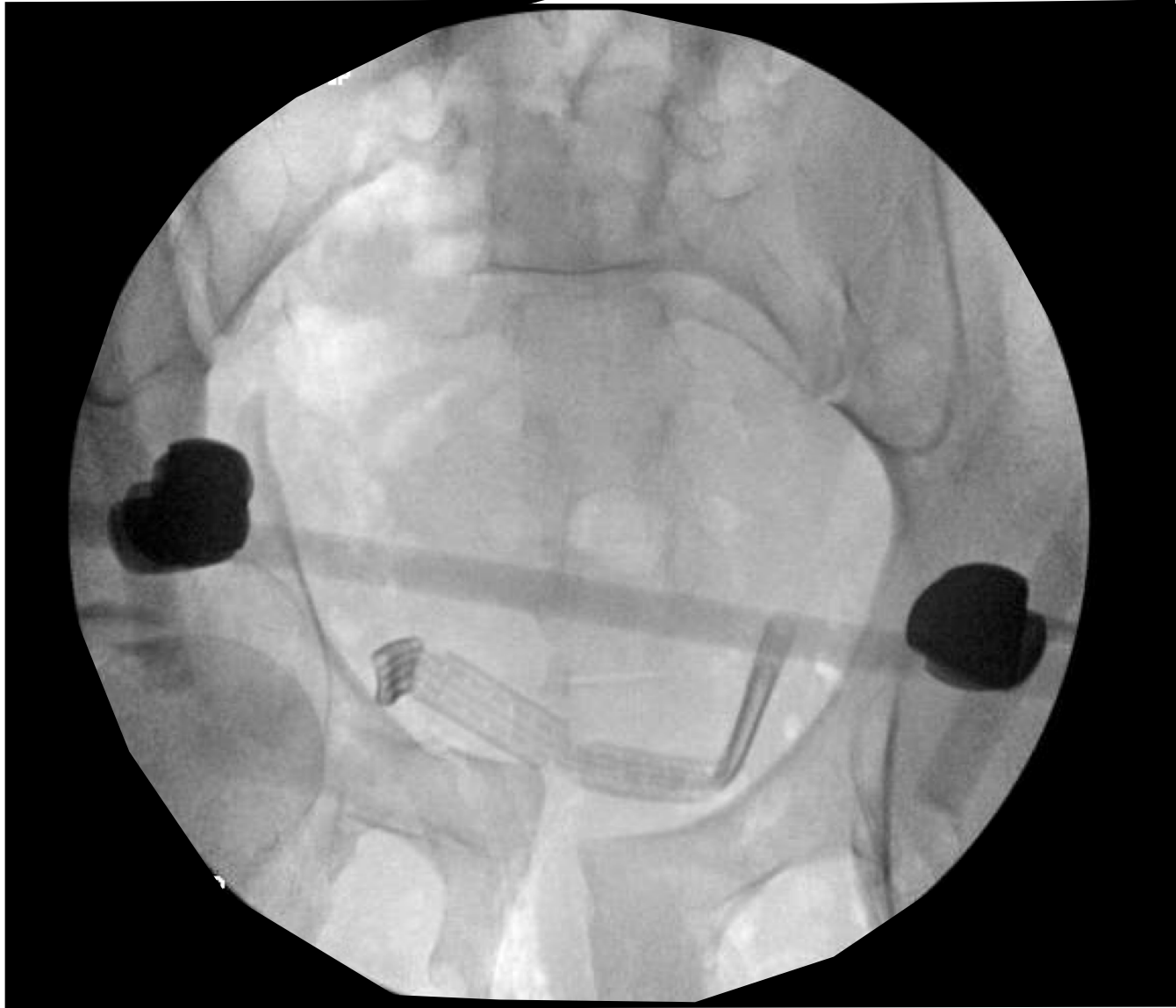


FIG 3 The pelvis was reduced with traction . The hip and knee were flexed A) pre reduction B) after maneuver

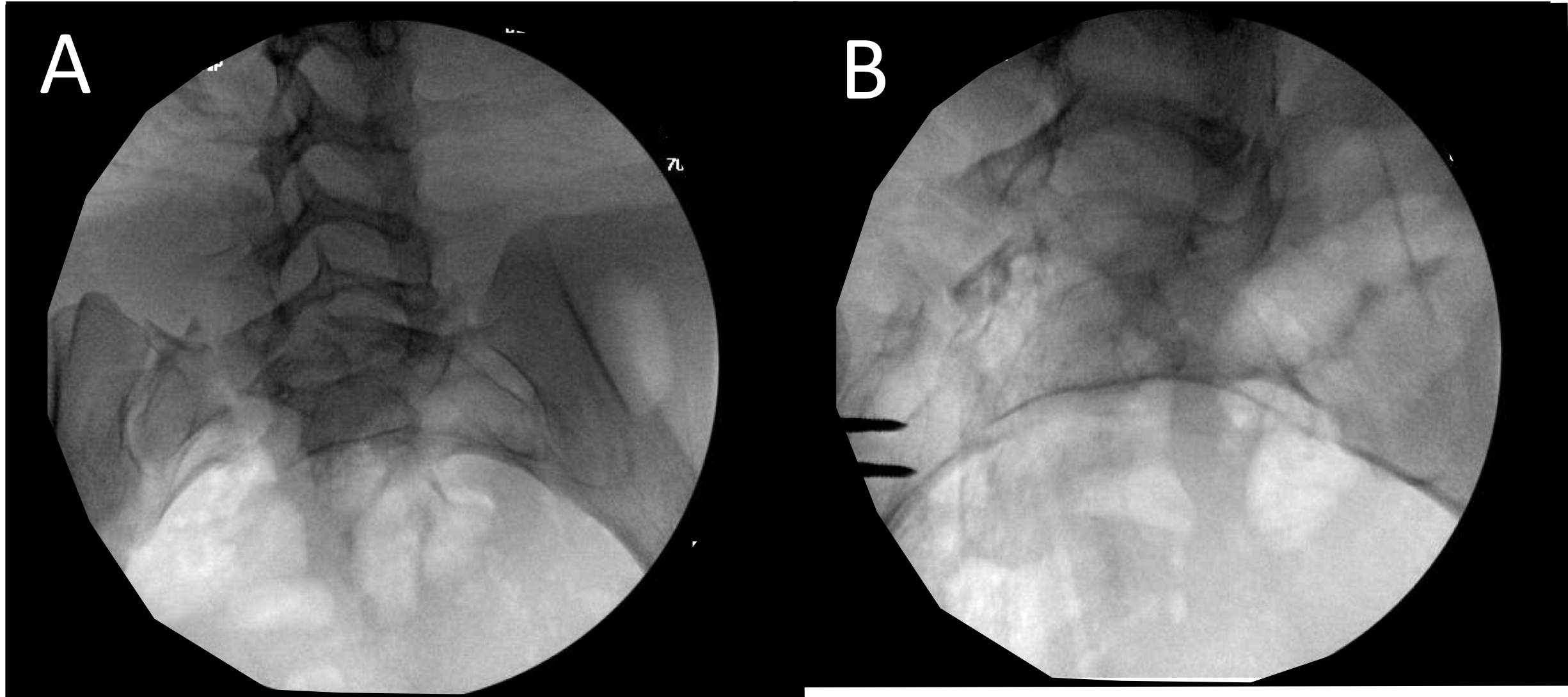


FIG 4 Posterior reduction and fixation with SI screw and a Trans- sacral screw

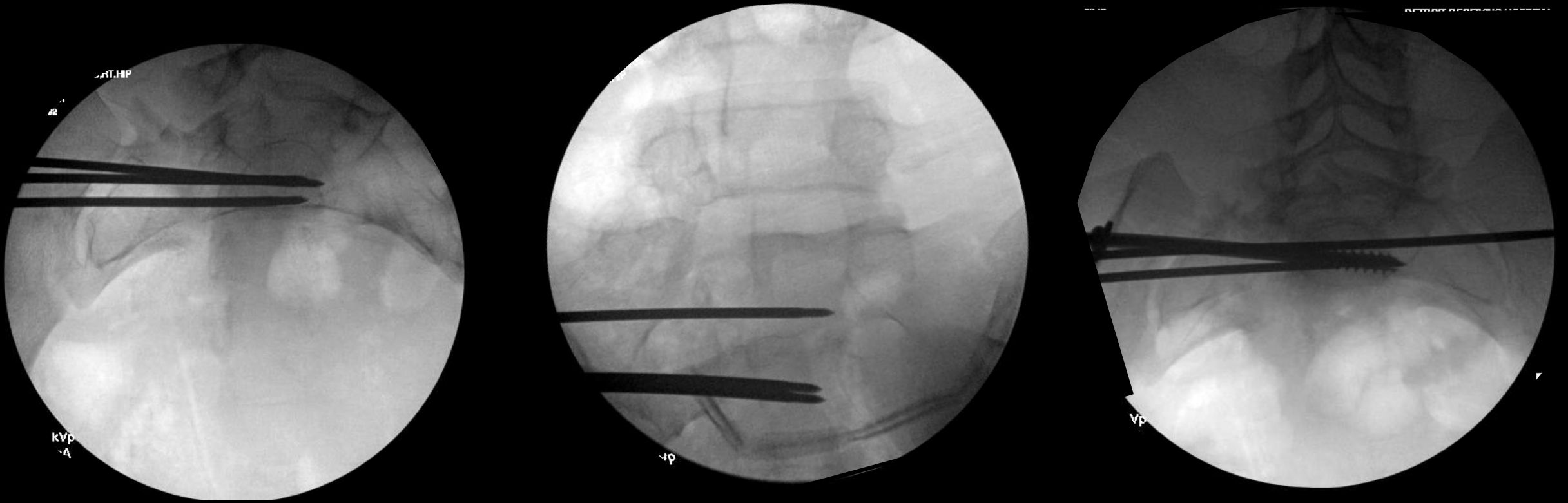

FIG 5 Posterior Fixation with an S1
SI screw and S2 Trans-sacral screw

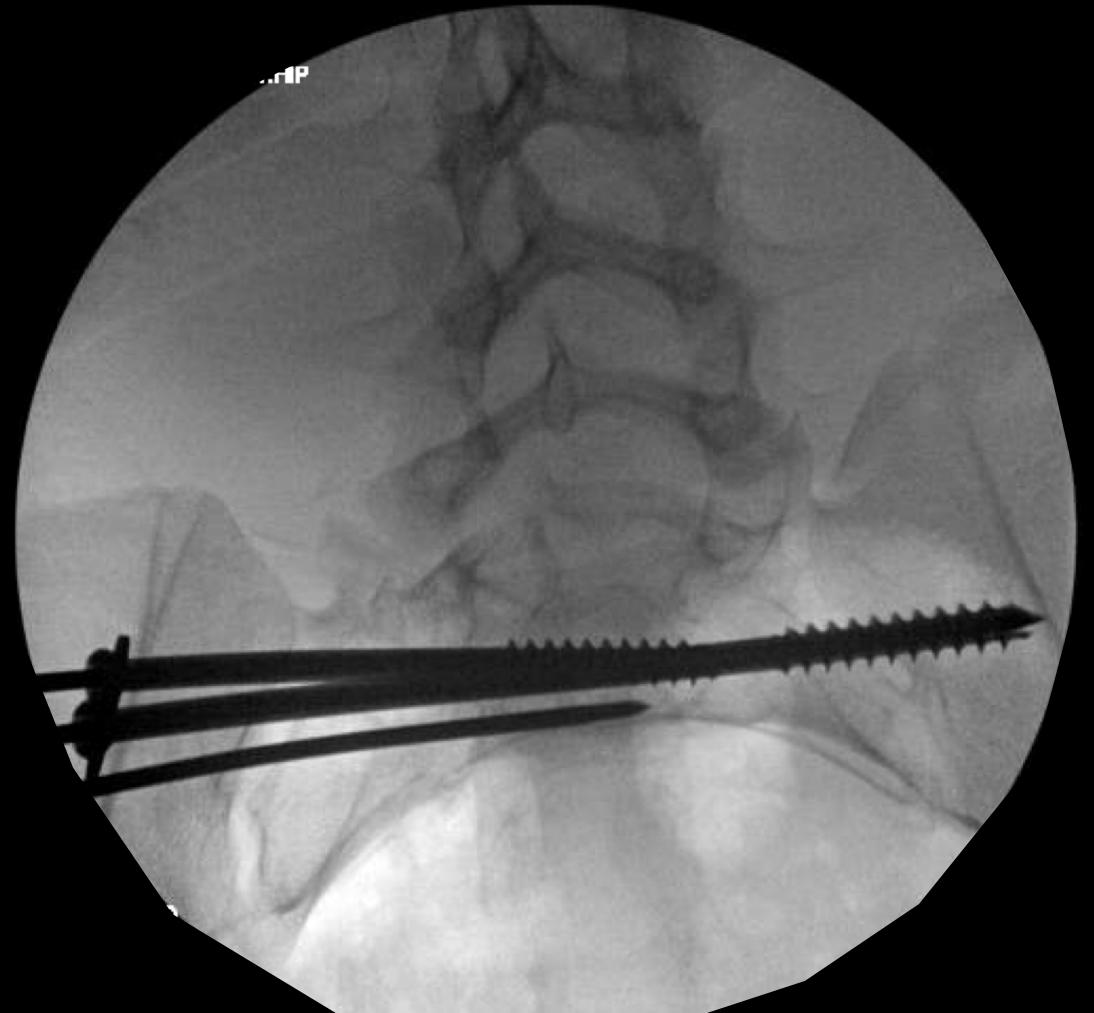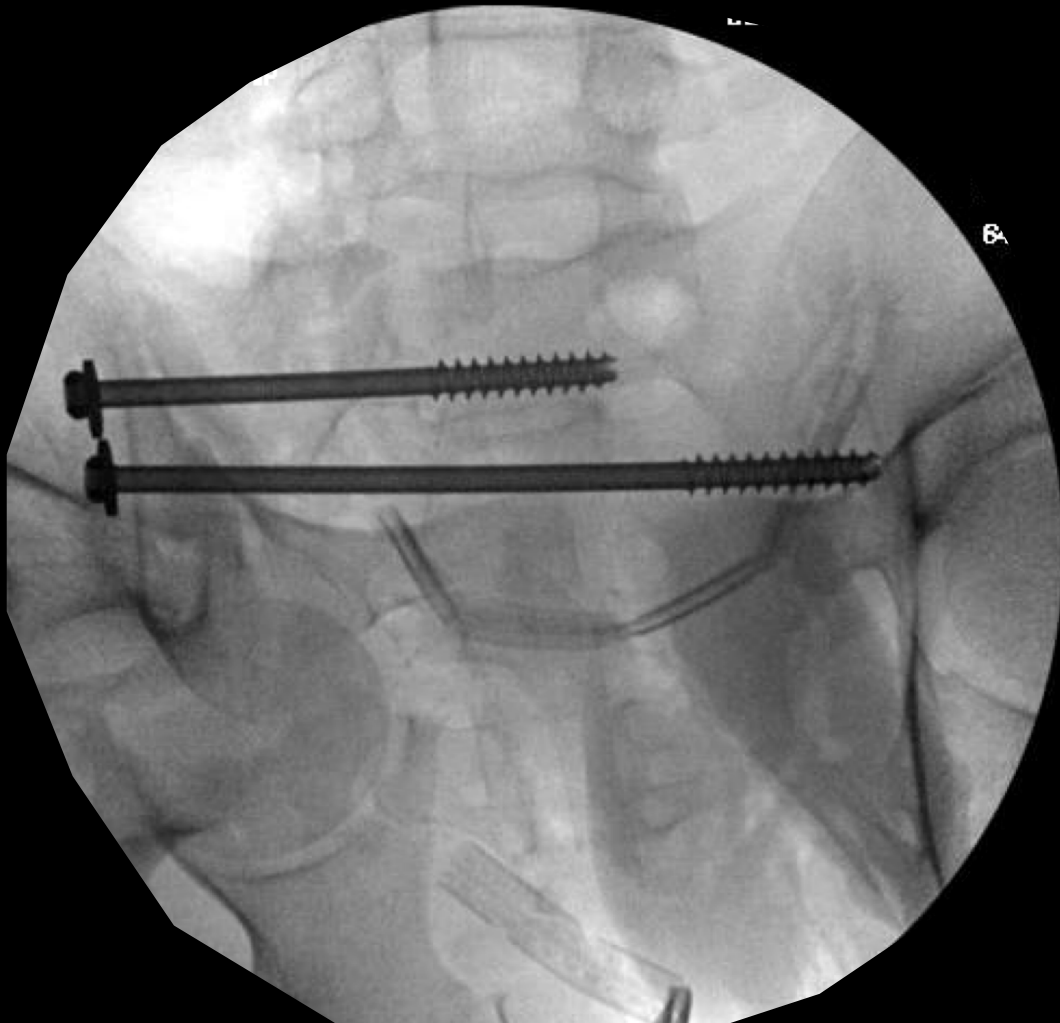


FIG 6 Progressing forward with a percutaneous fixation of anterior ramus and INFIX used to close the front of a comminuted anterior pelvic injury

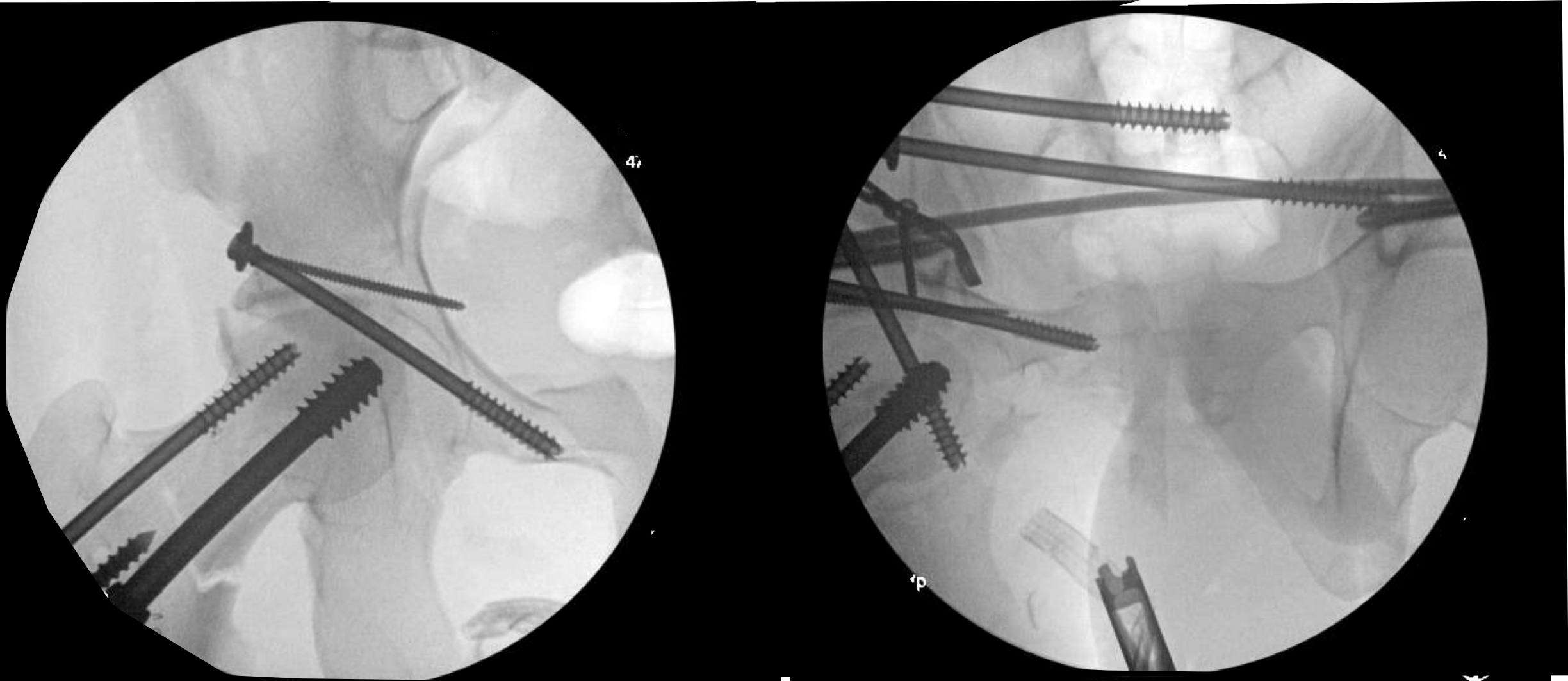


FIG 7 Final reinforcement with triangular fixation

