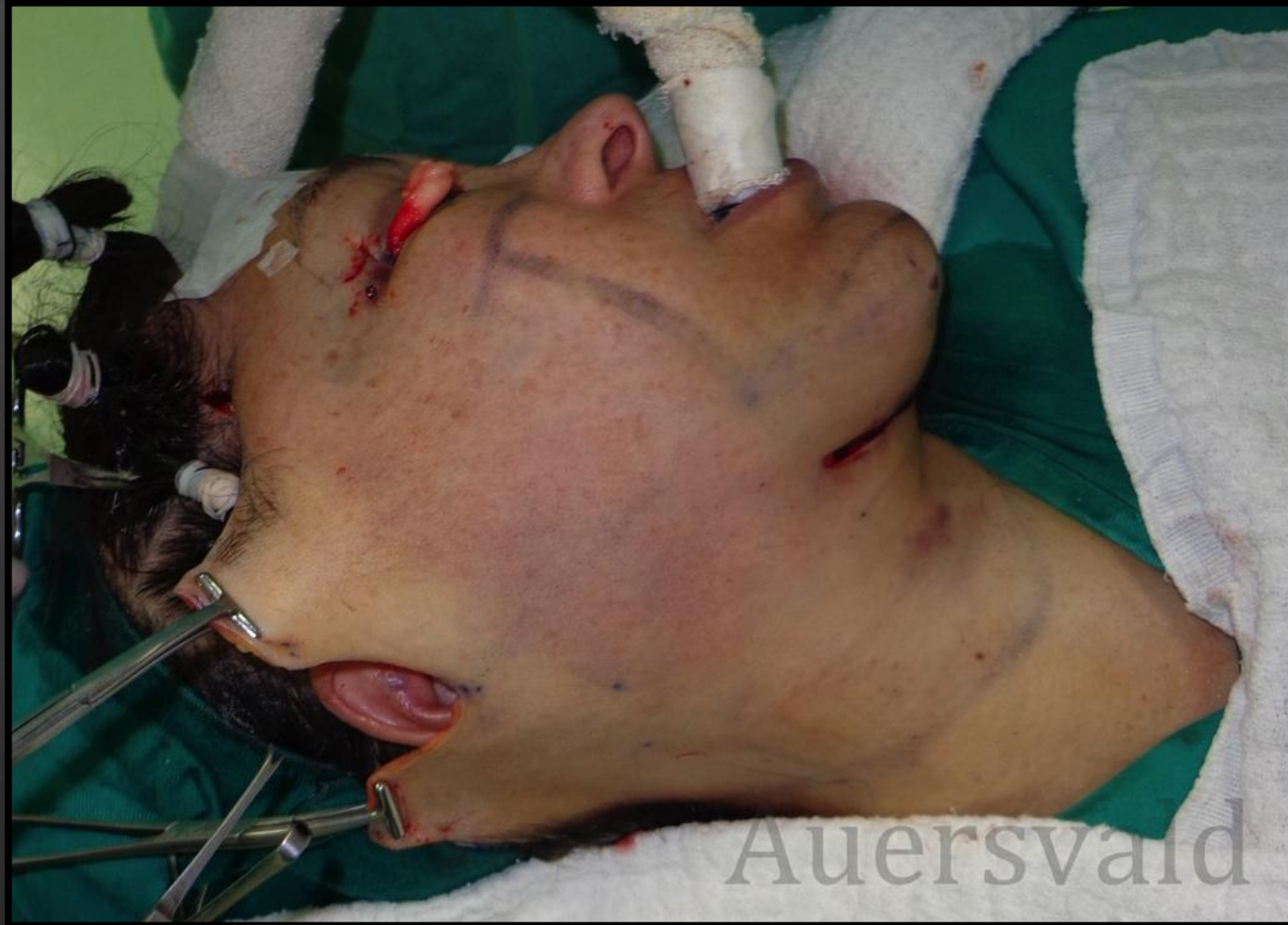

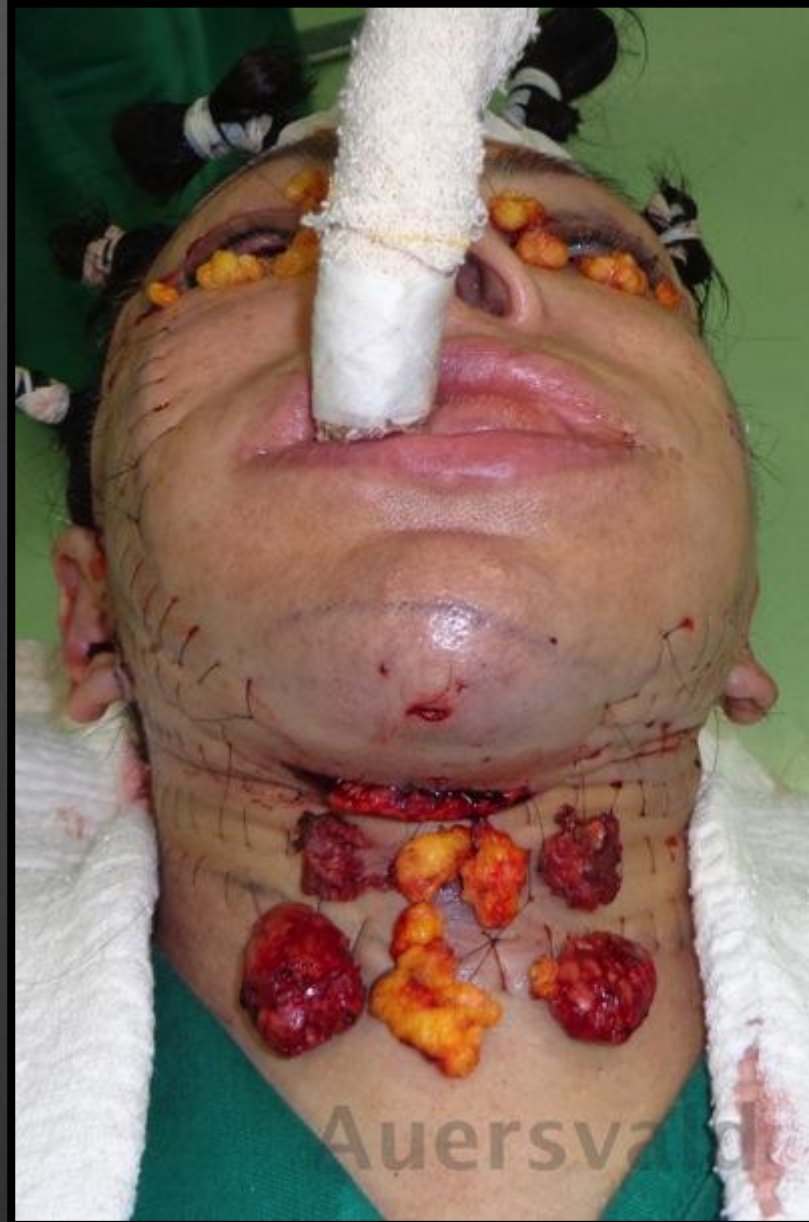Submandibular Salivary Gland  
Partial Resection  
Illustrative Case

Andre Auersvald  
Luiz Augusto Auersvald  
Curitiba, Parana  
Brazil

Flap traction

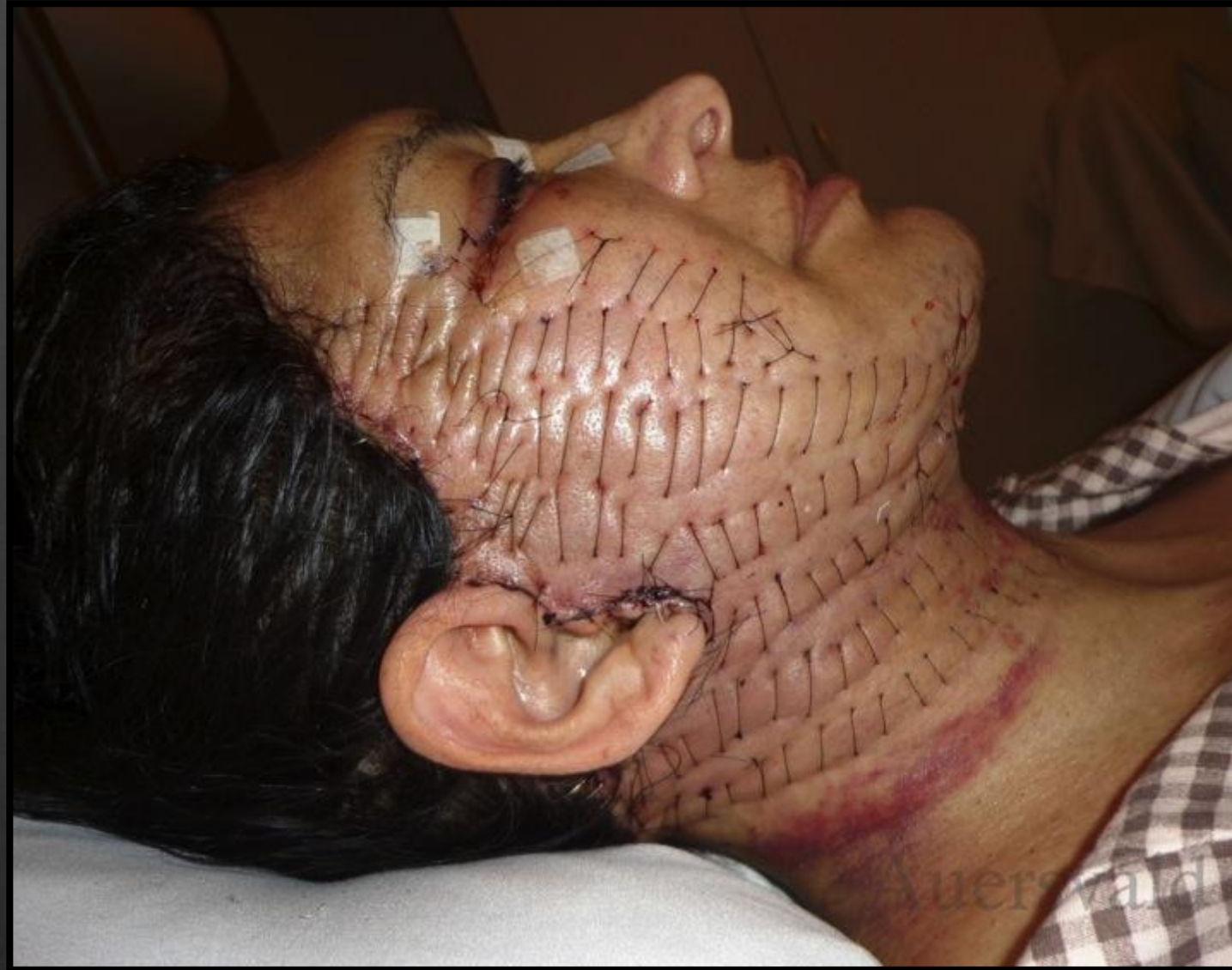

Lid bags, Digastric, Sub mandibular gland, Interplatismal fat



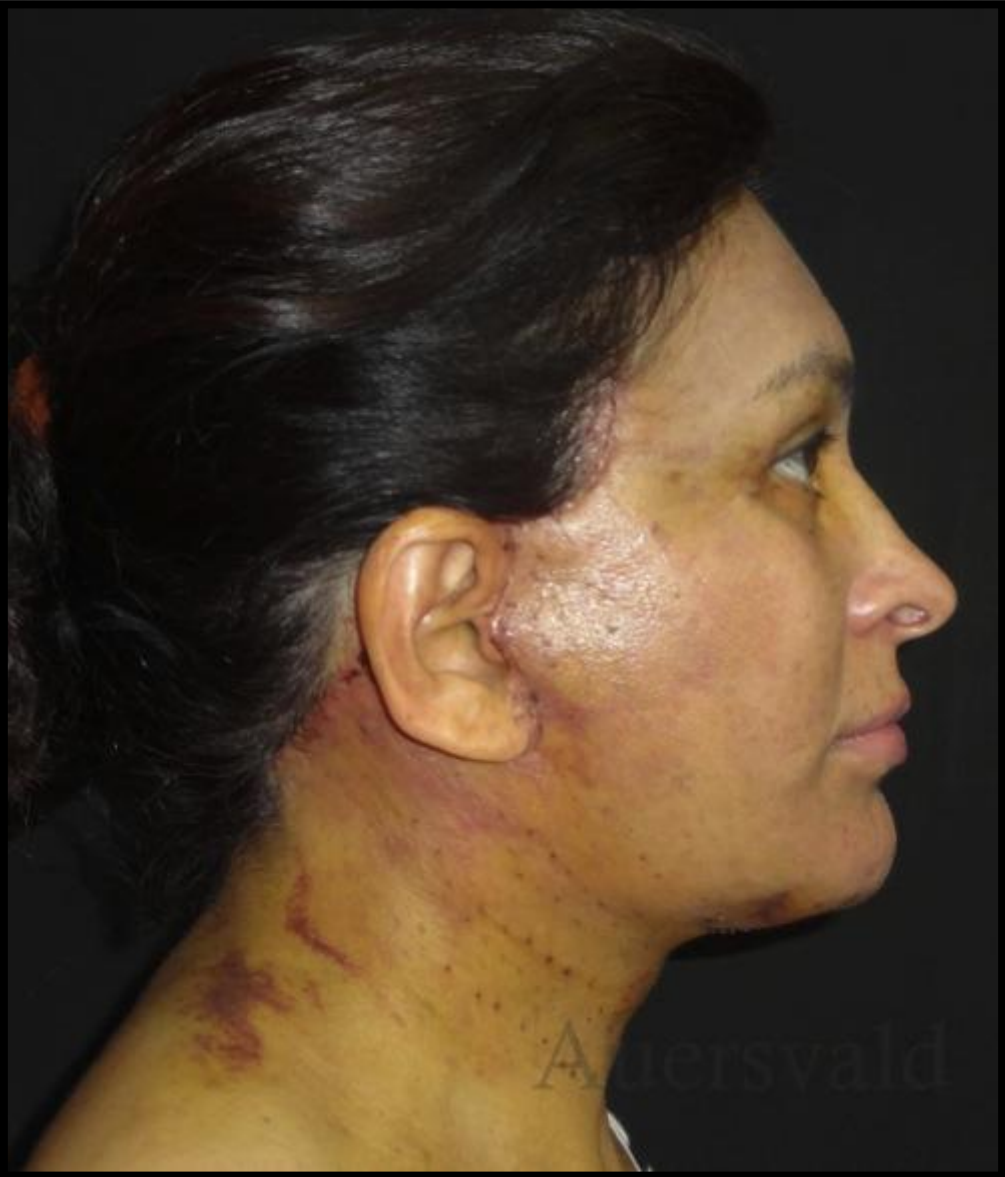Auersva

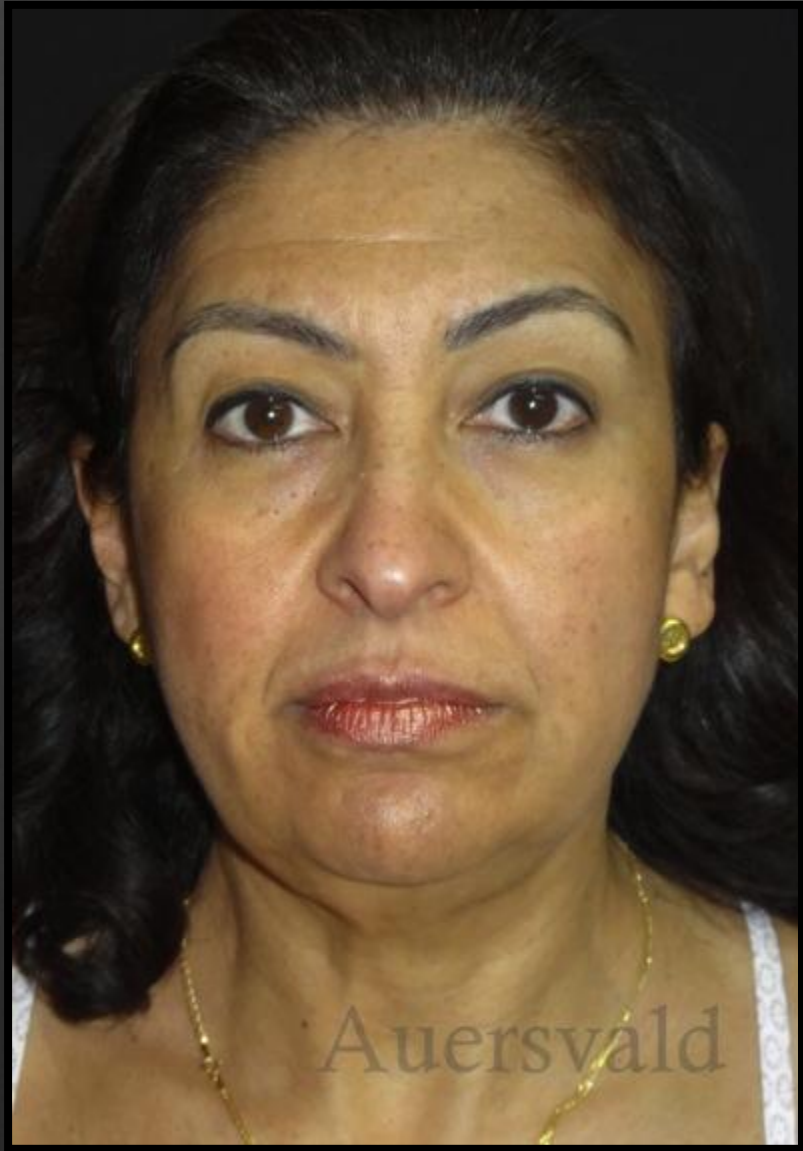
24 h, Hemostatic Net (Auersvald\*)



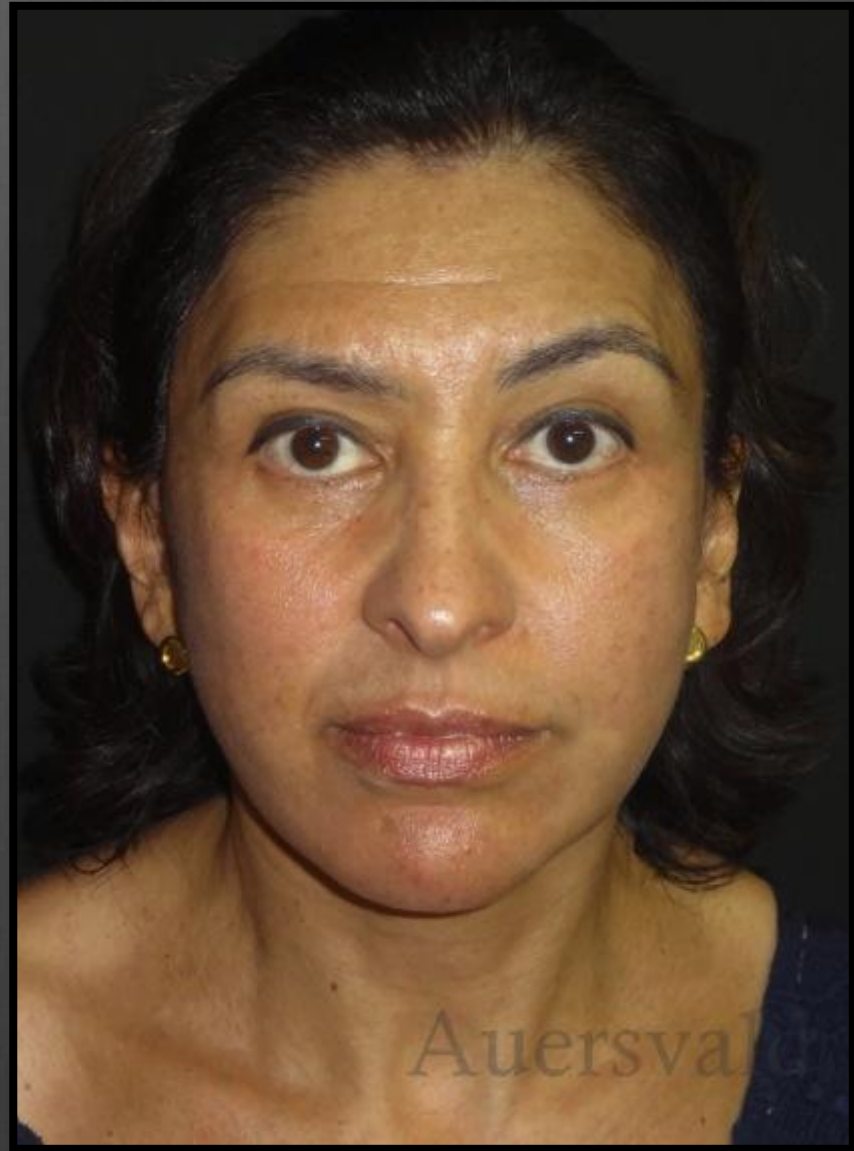\*Auersvald A and Auersvald L.A. *Aesth Plast Surg.* 2014; 38: 1-9.

8<sup>th</sup> day

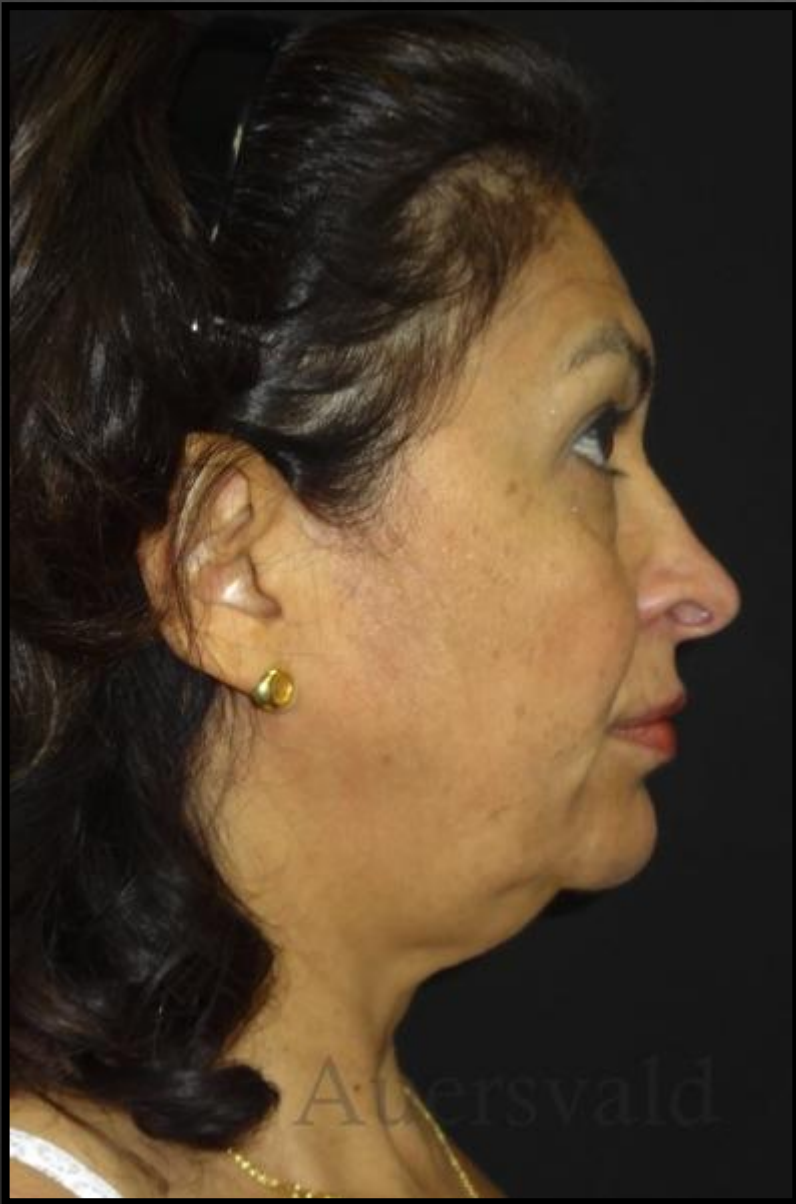



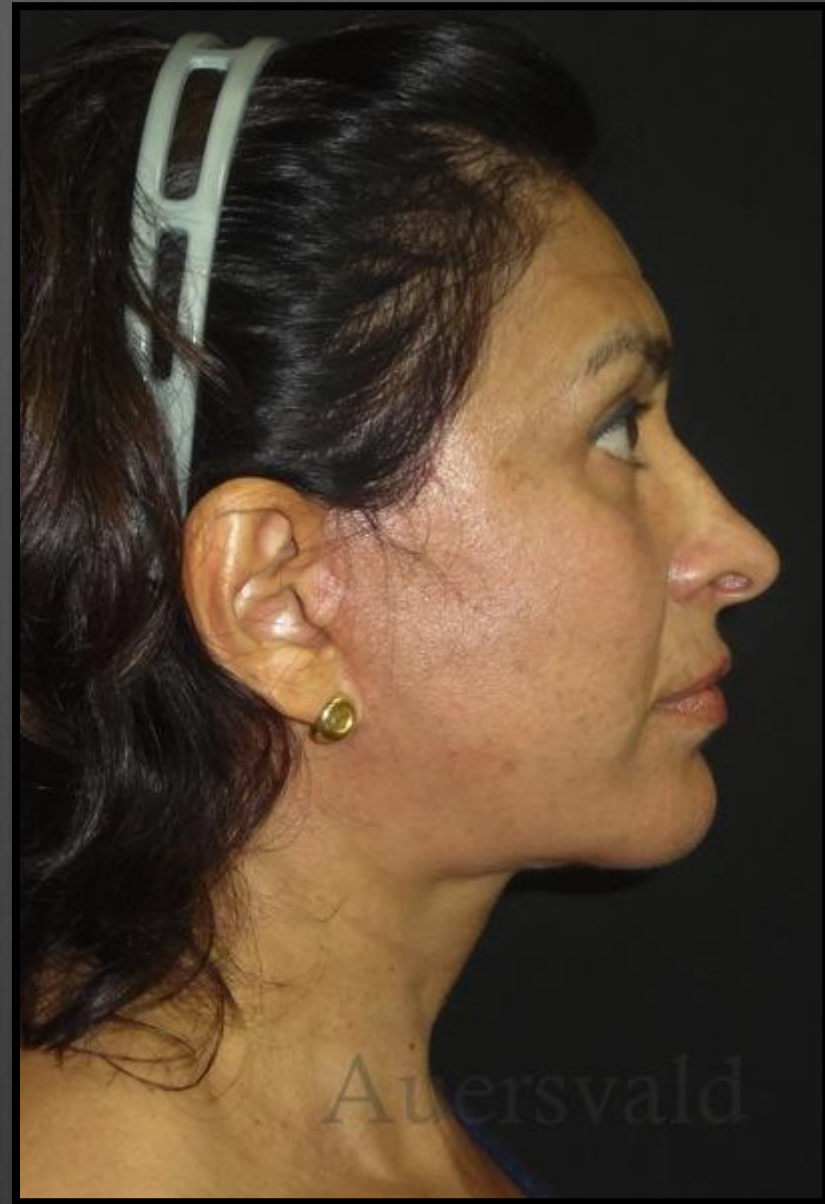Pre



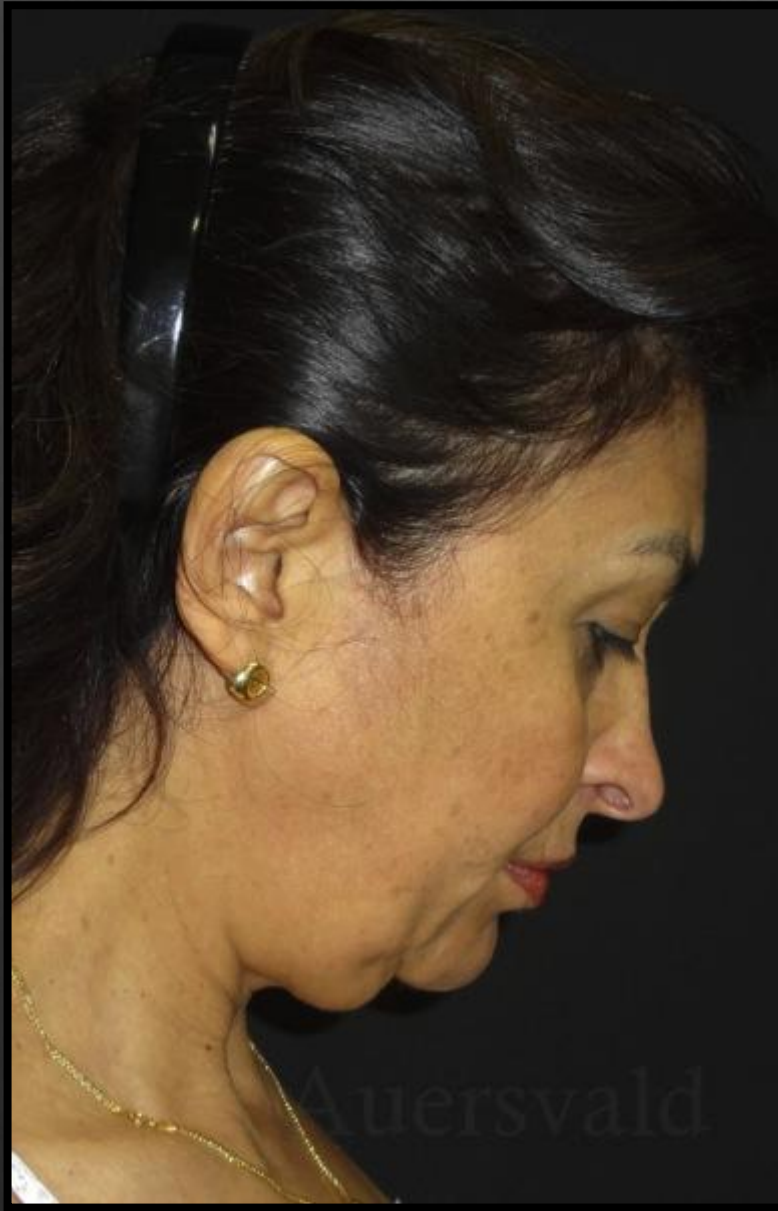10 months



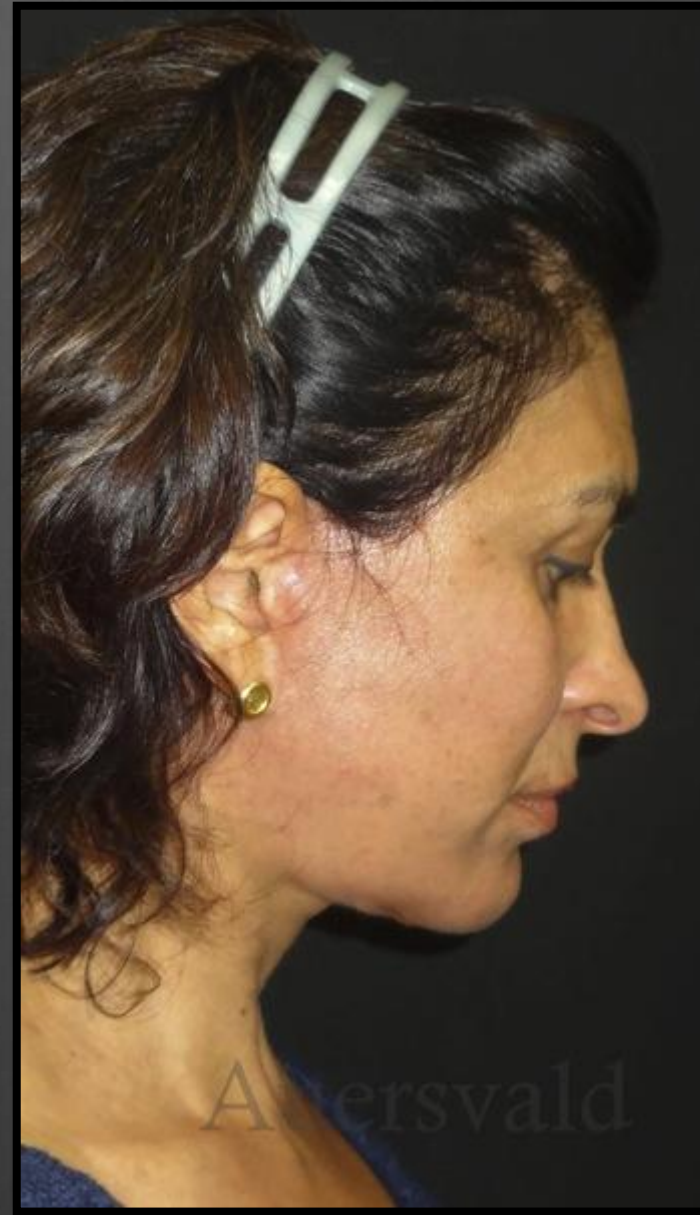Pre



10 months



Pre



10 months